

VENTANA ALK (D5F3) CDx Assay

REF 790-4796

06687199001

IVD  50

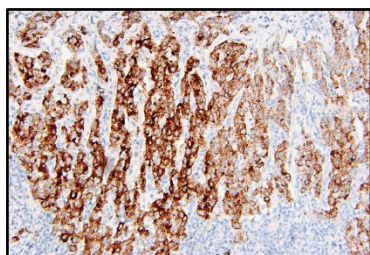


Figure 1. VENTANA ALK (D5F3) CDx Assay staining in non-small cell lung carcinoma.

INTENDED USE

VENTANA ALK (D5F3) CDx Assay is intended for the qualitative detection of the anaplastic lymphoma kinase (ALK) protein in formalin-fixed, paraffin-embedded (FFPE) non-small cell lung carcinoma (NSCLC) tissue stained with a BenchMark XT automated staining instrument. It is indicated as an aid in identifying patients eligible for treatment with XALKORI® (crizotinib).

ASSAY INTERPRETATION

This product should be interpreted by a

qualified pathologist in conjunction with histological examination, relevant clinical information, and proper controls.

This product is intended for *in vitro* diagnostic (IVD) use.

SUMMARY AND EXPLANATION

The anaplastic lymphoma kinase (ALK) protein is a member of the insulin receptor superfamily of receptor tyrosine kinases.¹ ALK is a type I membrane glycoprotein that is normally expressed in the nervous system.² The ALK gene resides at chromosome 2p23 and is constructed of 2 large introns and 26 exons.¹ The molecular pathogenesis of ALK begins with chromosomal rearrangements that partner the 3' coding sequences for the ALK intracellular signaling domain with the 5' promoter elements and coding sequences of other genes. The 5' promoter elements and coding sequences drive overexpression and ligand-independent oligomerization of the chimeric proteins, features common in fusion-type protein tyrosine kinase human neoplasms.

An inversion within chromosome 2p resulting in the formation of a fusion gene product comprising portions of the echinoderm microtubule associated protein-like 4 (EML4) gene and the ALK gene was discovered in 2007 in NSCLC cell lines and archived clinical specimens.³ A subsequent series of published studies indicated that EML4-ALK inversion events produced >9 catalytically active kinase fusion protein variants, each containing the same portion of the ALK C-terminal kinase domain.⁴⁻⁸ As with ALK gene fusions first identified in anaplastic large-cell lymphoma (ALCL), the EML4-ALK fusion protein was shown to have transforming activity. Consistent with this, EML4-ALK expression in lung alveolar epithelial cells in transgenic mice has been reported to be a potent oncogenic factor.⁹

CLINICAL SIGNIFICANCE

NSCLC is the most common type of lung cancer. There are three common types of NSCLC: adenocarcinoma, squamous cell carcinoma, and large cell carcinoma.

ALK is now recognized as a key oncogenic driver in NSCLC, and although EML4 is the predominant fusion partner, other fusion partner genes have been identified.^{10,11} The incidence of ALK gene rearrangements appears to range from 2–7%, translating to approximately 6,000 ALK-positive patients/year in the United States (US) and 40,000 patients/year worldwide.^{3,4,7}

Small tissue samples may be easily used in routine immunohistochemistry (IHC), making this technique, in combination with antibodies that detect antigens important for carcinoma interpretation, an effective tool for the pathologist in their diagnosis and prognosis of disease. One important marker in NSCLC is ALK.

The vast majority of ALK gene rearrangements were observed in lung adenocarcinoma specimens compared with squamous or small cell histologies.³⁻⁸ Some evidence suggests a correlation between ALK gene rearrangements and NSCLC in patients of "never or light" smoking status, although this may not be a statistically significant cofactor.^{3,4,7,9}

Importantly, ALK gene rearrangements are rarely coincident with EGFR, HER2, or KRAS mutations, demonstrating that ALK positivity is a distinct disease subtype.⁹

XALKORI® is a selective ATP-competitive small-molecule inhibitor of the ALK, ROS1 and c-Met/Hepatocyte Growth Factor Receptor (HGFR) tyrosine kinases and their oncogenic variants (e.g., ALK or ROS1 fusion proteins or c-Met/HGFR mutant variants). XALKORI® has demonstrated concentration-dependent inhibition of ALK and c-Met phosphorylation in cell-based assays using tumor cell lines. It has also demonstrated antitumor activity in mice bearing tumor xenografts expressing EML4- or NPM-ALK fusion proteins or Met.^{12,13}

The clinical significance of ALK gene rearrangements has been demonstrated in randomized, active controlled, clinical trials of XALKORI® conducted by Pfizer.¹⁴ In the United States, XALKORI® is indicated for the treatment of patients with metastatic NSCLC whose tumors are ALK-positive as detected by a FDA-approved test. Ventana has demonstrated concordance of the VENTANA ALK (D5F3) CDx Assay with the Abbott Vysis ALK Break Apart FISH Probe Kit (ALK FISH) in determining the ALK status of a patient's NSCLC. ALK FISH can present technical challenges in evaluating the staining results. As stated by Galetta et al., intrachromosomal re-arrangements can yield subtle signal-splitting, leading to potential false negatives.¹⁵ Recent studies indicate that IHC is sensitive and specific for determining ALK status, and is a viable alternative to ALK FISH.^{10,11,15-17} Ventana has developed the VENTANA ALK (D5F3) CDx Assay and scoring algorithm to determine ALK status in NSCLC specimens.

Interpretation of the results of VENTANA ALK (D5F3) CDx Assay staining of tissue samples should be made using the recommended scoring algorithm. Histological tissue preparations have the advantage of intact tissue morphology to aid in the interpretation of the ALK positivity of the sample. All histological tests should be interpreted by a pathologist, and the results should be complemented by morphological studies and proper controls and used in conjunction with other clinical and laboratory data. Target antigens of IHC assays are impacted by fixation time, type of fixative, and age of cut slides so care must be taken to ensure compatibility of specimen preparation prior to staining (refer to the Interpretation Guide for VENTANA ALK (D5F3) CDx Assay for Non-Small Cell Lung Carcinoma (NSCLC) P/N 1012345 and the Specific Limitations section below).

PRINCIPLE OF THE PROCEDURE

VENTANA ALK (D5F3) CDx Assay is a rabbit monoclonal primary antibody that binds to ALK in paraffin-embedded tissue sections. The specific antibody can be visualized using OptiView DAB IHC Detection Kit (Cat. No. 760-700 / 06396500001) followed by the OptiView Amplification Kit (Cat. No. 760-099 / 06396518001 (50 test) or 860-099 / 06718663001 (250 test)). Refer to the appropriate OptiView DAB IHC Detection Kit and OptiView Amplification Kit package inserts for further information.

REAGENT PROVIDED

VENTANA ALK (D5F3) CDx Assay includes a recombinant rabbit monoclonal antibody and contains sufficient reagent for staining 50 slides.

One 5 mL dispenser of VENTANA ALK (D5F3) CDx Assay contains approximately 70 µg of the rabbit monoclonal (D5F3) antibody.

The antibody is diluted in 0.08 M PBS with 3% carrier protein and 0.05% ProClin 300, a preservative.

Total protein concentration of the reagent is approximately 10 mg/mL. Specific antibody concentration is approximately 14 µg/mL.

MATERIALS AND REAGENTS NEEDED BUT NOT PROVIDED

The following reagents and materials may be required for staining but are not provided:

- Human appendix or ALK-positive and ALK-negative non-small cell lung carcinoma specimens for use as control tissue
- Rabbit Monoclonal Negative Control Ig (Cat. No. 790-4795 / 06683380001)
- Microscope slides, positively charged
- Drying oven capable of maintaining a temperature of 60°C ± 5°C
- Bar code labels
- Xylene (Histological grade)
- Ethanol or reagent alcohol (Histological grade)
 - 100% solution: Undiluted ethanol or reagent alcohol
 - 95% solution: Mix 95 parts of ethanol or reagent alcohol with 5 parts of deionized water

- 80% solution: Mix 80 parts of ethanol or reagent alcohol with 20 parts of deionized water
- 8. Deionized or distilled water
- 9. OptiView DAB IHC Detection Kit (Cat. No. 760-700 / 06396500001)
- 10. OptiView Amplification Kit (Cat. No. 760-099 / 06396518001(50 test) or 860-099 / 06718663001 (250 test))
- 11. EZ Prep Concentrate (10X) (Cat. No. 950-102 / 05279771001)
- 12. Reaction Buffer Concentrate (10X) (Cat. No. 950-300 / 05353955001)
- 13. LCS (Predilute) (Cat. No. 650-010 / 05264839001)
- 14. Cell Conditioning 1(CC1) (Cat. No. 950-124 / 05279801001)
- 15. Hematoxylin II Counterstain (Cat. No. 790-2208 / 05277965001)
- 16. Bluing Reagent (Cat. No. 760-2037 / 05266769001)
- 17. Permanent mounting medium (Permount Fisher Cat. No. SP15-500 or equivalent)
- 18. Cover glass (sufficient to cover tissue, such as VWR Cat. No. 48393-060)
- 19. Automated coverslipper (such as the Tissue-Tek SCA Automated Coverslipper)
- 20. Light microscope
- 21. Absorbent wipes
- 22. BenchMark XT

Staining reagents, such as VENTANA detection kits and ancillary components, including negative and positive tissue control slides, are not provided.

Reconstitution, Mixing, Dilution, Titration

This antibody is optimized for use on VENTANA BenchMark XT automated slide stainers in combination with OptiView DAB IHC Detection Kit and OptiView Amplification Kit. No reconstitution, mixing, dilution, or titration is required.

STORAGE

Upon receipt and when not in use, store at 2–8°C. Do not freeze.

To ensure proper reagent delivery and stability of the antibody, replace the dispenser cap after every use and immediately place the dispenser in the refrigerator in an upright position.

Every antibody dispenser is expiration dated. When properly stored, the reagent is stable to the date indicated on the label. Do not use reagent beyond the expiration date.

SPECIMEN COLLECTION AND PREPARATION FOR ANALYSIS

Routinely processed, FFPE tissues are suitable for use with this primary antibody when used with VENTANA detection kits and a VENTANA BenchMark XT automated slide stainer.

On the basis of xenograft models generated from the NCI-H2228 human NSCLC cell-line, which is positive for ALK, Ventana recommends tissue fixation in 10% neutral buffered formalin (NBF) for at least 6 hours.¹⁸ Fixation times of less than 6 hours result in a significant loss of staining intensity for ALK. Zinc formalin fixative also is acceptable at a fixation time of at least 6 hours. The amount used should be 15 to 20 times the volume of tissue. No fixative will penetrate more than 2 to 3 mm of solid tissue or 5 mm of porous tissue in a 24-hour period. Fixation can be performed at room temperature (15°C — 25°C).¹⁹

Fixatives such as alcohol-formalin-acetic acid (AFA), Prefer fixative, B5, and other acid and/or alcohol-containing fixatives have demonstrated a loss of staining intensity for ALK at all fixation times tested (1—72 hours). They are not recommended for use with this assay. Delay-to-fixation studies also revealed a loss of staining intensity for ALK when xenograft specimens were not fixed within 6 hours of excision. See the Interpretation Guide for VENTANA ALK (D5F3) CDx Assay for Non-Small Cell Lung Carcinoma (NSCLC) P/N 1012345 for further discussion of the impact of specimen preparation on ALK staining intensity.

Sections should be cut approximately 4 µm thick and mounted on positively-charged glass slides. Slides should be stained promptly, as antigenicity of cut tissue sections may diminish over time and is compromised within 3 months after cutting from the paraffin block (see the Interpretation Guide for VENTANA ALK (D5F3) CDx Assay for Non-Small Cell Lung Carcinoma (NSCLC) P/N 1012345 and the Performance Characteristics section below).

WARNINGS AND PRECAUTIONS

1. For *in vitro* diagnostic (IVD) use.
2. For professional use only.

3. ProClin 300 solution is used as a preservative in this reagent. It is classified as an irritant and may cause sensitization through skin contact. Take reasonable precautions when handling. Avoid contact of reagents with eyes, skin, and mucous membranes. Use protective clothing and gloves.
4. Materials of human or animal origin should be handled as biohazardous materials and disposed of with proper precautions.
5. Avoid contact of reagents with eyes and mucous membranes. If reagents come in contact with sensitive areas, wash with copious amounts of water.
6. Avoid microbial contamination of reagents as it may cause incorrect results.
7. Consult local and/or state authorities with regard to recommended method of disposal.
8. For supplementary safety information, refer to the product Safety Data Sheet and the Symbol and Risk Phrase Guide located at www.ventana.com.

VENTANA ALK (D5F3) CDx ASSAY-SPECIFIC STAINING PROCEDURE

VENTANA ALK (D5F3) CDx Assay has been developed for use on a VENTANA BenchMark XT automated slide stainer in combination with Rabbit Monoclonal Negative Control Ig, OptiView DAB IHC Detection Kit, OptiView Amplification Kit, and ancillary reagents. An assay-specific staining procedure must be used with the VENTANA ALK (D5F3) CDx Assay. Refer to Table 1 for the recommended staining protocol and required staining procedure. Any deviation from recommended test procedures may invalidate expected results. Appropriate controls must be employed and documented. Users who deviate from recommended test procedures must accept responsibility for interpretation of patient results.

Table 1. Recommended Staining Protocol for VENTANA ALK (D5F3) CDx Assay and Rabbit Monoclonal Negative Control Ig with OptiView DAB IHC Detection Kit and OptiView Amplification Kit on a BenchMark XT Automated Slide Stainer.

Staining Procedure: XT VENTANA ALK(D5F3) CDx Assay	
Protocol Step	Parameter Input
Antibody (Primary)	V-ALK (D5F3) Or Rabbit Monoclonal Negative Control Ig
OptiView HQ Univ Linker	12 Minutes
Counterstain	Hematoxylin II, 4 Minutes
Post Counterstain	Bluing, 4 Minutes

QUALITY CONTROL PROCEDURES

Rabbit Monoclonal Negative Control Ig

A matched negative reagent control slide must be run for every specimen to aid in the interpretation of results. Rabbit Monoclonal Negative Control Ig (Cat. No. 790-4795 / 06683380001), a negative reagent control antibody, is specifically matched for this assay and is used in place of the primary antibody to evaluate nonspecific staining. The staining procedure for the negative reagent control should equal the primary antibody incubation period. Use of a different negative control reagent, or failure to use the recommended negative control reagent, may cause false results.

System-Level Controls

System-level controls must be run with patient samples. They can be either human appendix²⁰ or known ALK-positive/negative NSCLC tissue samples.

Control tissue should be autopsy, biopsy, or surgical specimens prepared and fixed as soon as possible in a manner identical to test sections. Such tissue may monitor all steps of the analysis, from tissue preparation through staining. Use of a tissue section fixed or processed differently from the test specimen provides control for all reagents and method steps except fixation and tissue preparation.

Appendix or ALK Positive/Negative NSCLC Tissue Controls

An ALK-positive and an ALK-negative control tissue fixed and processed in the same manner as the patient specimens can be run for each set of test conditions and with every VENTANA ALK (D5F3) CDx Assay staining procedure performed.

NSCLC cases with staining representative of clinically ALK-positive and clinically ALK-negative results are suitable for optimal quality control, including detection of minor levels of reagent degradation or instrument out-of-specification issues.

Human appendix tissue contains positive and negative staining elements for the ALK protein and is also suitable for use as a system-level control. The positive staining tissue components are used to confirm that the antibody was applied and the instrument functioned properly; while the negative staining elements are used to detect minor levels of reagent degradation or instrument out-of-specification issues.

Appropriate staining of ALK-positive and negative NSCLC and appendix tissue components is described in Table 2 and Table 3 and in the Interpretation Guide for VENTANA ALK (D5F3) CDx Assay for Non-Small Cell Lung Carcinoma (NSCLC) P/N 1012345.

Known positive and known negative tissue controls should be utilized only for monitoring the correct performance of processed tissues and test reagents.

Assay Verification

Prior to initial use of an antibody or staining system in a diagnostic procedure, the specificity of the antibody should be verified by testing it on a series of tissues with known IHC performance characteristics representing ALK-positive and -negative tissues (refer to the Quality Control Procedures previously outlined in this section of the product insert and to the Quality Control recommendations of the College of American Pathologists Laboratory Accreditation Program, Anatomic Pathology Checklist²¹ or the CLSI Approved Guideline²²). These quality control procedures should be repeated for each new antibody lot, or whenever there is a change in assay parameters. NSCLC tissues with known ALK status, or human appendix samples, are suitable for assay verification.

INTERPRETATION OF RESULTS

The VENTANA automated immunostaining procedure causes a brown colored DAB reaction product to precipitate at the antigen sites localized by the VENTANA ALK (D5F3) CDx Assay antibody. A qualified pathologist experienced in IHC procedures must evaluate system-level controls and qualify the stained product before interpreting results.

Positive/Negative System-Level Tissue Controls

The stained positive and negative tissue controls should be examined to ascertain that all reagents are functioning properly. The presence of an appropriately colored reaction product on the positive control tissue within the cytoplasm of the target cells is indicative of positive reactivity.

If the positive or negative tissue controls fail to demonstrate appropriate staining or demonstrate a change in clinical diagnostic interpretation, any results with the test specimens should be considered invalid.

Table 2. Appendix Tissue Control Evaluation Criteria. Representative images are provided in the Interpretation Guide for VENTANA ALK (D5F3) CDx Assay for Non-Small Cell Lung Carcinoma (NSCLC) P/N 1012345.

Acceptable	Unacceptable
Presence of strong granular cytoplasmic staining in ganglion cells. (See note)	Absence of strong granular cytoplasmic staining in ganglion cells.
Absence of strong granular cytoplasmic staining in glandular epithelial cells, muscle, and lymphoid tissue (scant or rare staining of lymphoreticular cells may be observed in lymphoid aggregates).	Excessive non-specific background staining of glandular epithelial cells, muscle, or lymphoid tissue that interferes with scoring.

Note: The nerve in appendix muscular layers shows positive staining.

Negative Reagent Control

Nonspecific staining, if present, will have a diffuse appearance and can be evaluated using the negative reagent control slide stained with Rabbit Monoclonal Negative Control Ig. Intact cells should be used for interpretation of staining results, as necrotic or degenerated cells often stain nonspecifically. If background staining is excessive, results from the test specimen should be considered invalid. Examples of acceptable levels of background staining for this assay can be found in the Interpretation Guide for VENTANA ALK (D5F3) CDx Assay for Non-Small Cell Lung Carcinoma (NSCLC) P/N 1012345.

Patient Tissue

Patient tissue must be evaluated according to the VENTANA ALK (D5F3) CDx Assay scoring algorithm provided in Table 3. Refer to the Interpretation Guide for VENTANA ALK (D5F3) CDx Assay for Non-Small Cell Lung Carcinoma (NSCLC) P/N 1012345.

Table 3. Scoring Algorithm for VENTANA ALK (D5F3) CDx Assay. Representative images are provided in the Interpretation Guide for VENTANA ALK (D5F3) CDx Assay for Non-Small Cell Lung Carcinoma (NSCLC) P/N 1012345.

Clinical Interpretation	Staining Description
Positive for ALK	<p>Presence of strong granular cytoplasmic staining in tumor cells (any percentage of positive tumor cells). Certain staining elements should be excluded, including:</p> <ul style="list-style-type: none"> • light cytoplasmic stippling in alveolar macrophages, • cells of neural origin (nerve and ganglion cells), • glandular epithelial staining, and • scattered lymphoreticular cells within lymphocytic infiltrates. <p>Some background staining also may be observed within normal mucosa in NSCLC (including mucin) and in necrotic tumor areas, which should be excluded from the clinical evaluation.</p>
Negative for ALK	Absence of strong granular cytoplasmic staining in tumor cells.

GENERAL LIMITATIONS

1. IHC is a multiple step diagnostic process that requires specialized training in the selection of the appropriate reagents, tissue selection, fixation, processing, preparation of the immunohistochemistry slide, and interpretation of the staining results.
2. Tissue staining is dependent on the handling and processing of the tissue prior to staining. Improper fixation, freezing, thawing, washing, drying, heating, sectioning, or contamination with other tissues or fluids may produce artifacts, antibody trapping, or false negative results. Inconsistent results may result from variations in fixation and embedding methods, or from inherent irregularities within the tissue.
3. Excessive or incomplete counterstaining may compromise proper interpretation of results.
4. The clinical interpretation of any positive staining, or its absence, must be evaluated within the context of clinical history, morphology, and other histopathological criteria. The clinical interpretation of any staining, or its absence, must be complemented by morphological studies and system-level controls as well as other diagnostic tests. It is the responsibility of a qualified pathologist to be familiar with the antibodies, reagents, and methods used to interpret the stained preparation. Staining must be performed in a certified licensed laboratory under the supervision of a pathologist who is responsible for reviewing the stained slides and assuring the adequacy of positive and negative controls.
5. Ventana Medical Systems, Inc. provides antibodies and reagents at optimal dilution for use when the provided instructions are followed. Any deviation from recommended test procedures may invalidate expected results. Appropriate controls must be employed and documented. Users who deviate from recommended test procedures must accept responsibility for interpretation of patient results.
6. This product is not intended for use in flow cytometry, performance characteristics have not been determined.
7. Reagents may demonstrate unexpected reactions in previously untested tissues. The possibility of unexpected reactions even in tested tissue groups cannot be completely eliminated because of biological variability of antigen expression in neoplasms, or other pathological tissues.²³
8. Tissues from persons infected with hepatitis B virus and containing hepatitis B surface antigen (HBsAg) may exhibit nonspecific staining with horseradish peroxidase.²⁴
9. False positive results may be seen because of non-immunological binding of proteins or substrate reaction products. They may also be caused by

pseudoperoxidase activity (erythrocytes), endogenous peroxidase activity (cytochrome C), or endogenous biotin (example: liver, brain, breast, kidney) depending on the type of immunostain used.²⁵

- As with any immunohistochemistry test, a negative result means that the antigen was not detected, not that the antigen was absent in the cells or tissue assayed.

SPECIFIC LIMITATIONS

- VENTANA ALK (D5F3) CDx Assay has been solely approved on the VENTANA BenchMark XT instrument with the OptiView DAB IHC Detection Kit and the OptiView Amplification Kit and is not approved with any other detection or automated staining instruments.
- A patient specimen slide should be stained with Rabbit Monoclonal Negative Control Ig (Cat. No. 790-4795 / 06683380001). Other negative control reagents are not suitable for this assay.
- This assay has not been validated for use with cytology smears or decalcified specimens.
- Patient tissue should be stained within 3 months of sectioning from the tissue block. Loss of staining performance has been observed with the VENTANA ALK (D5F3) CDx Assay on sections that have been stored at room temperature for longer than 3 months.
- Ventana recommends that samples be fixed at least 6 hours in 10% NBF or zinc formalin. Use of fixation times or fixative types other than those recommended can lead to false negative results. Fixatives such as AFA, Prefer fixative, B5, and other acid and/or alcohol-containing fixatives have demonstrated a loss of specific ALK protein staining. Refer to the Interpretation Guide for VENTANA ALK (D5F3) CDx Assay for Non-Small Cell Lung Carcinoma (NSCLC) P/N 1012345 for further discussion.
- Some staining artifacts have been noted with the VENTANA ALK (D5F3) CDx Assay. Light granular cytoplasmic stippling in alveolar macrophages may be present on both the VENTANA ALK (D5F3) CDx Assay and negative reagent control-stained slides, indicating that it is an artifact of the detection system and should not be evaluated as ALK positive staining. In addition, punctate staining has been observed on necrotic tumor areas; such staining should also be disregarded during patient sample evaluation. Staining of neural tissue, including nerve, and of occasional cells within infiltrating lymphocytes has been observed with VENTANA ALK (D5F3) CDx Assay antibody. Refer to the Interpretation Guide for VENTANA ALK (D5F3) CDx Assay for Non-Small Cell Lung Carcinoma (NSCLC) P/N 1012345 for further discussion.
- Slight variability in overall staining intensity may be observed on system-level (tissue) controls due to the OptiView Amplification Kit. Refer to the Interpretation Guide for VENTANA ALK (D5F3) CDx Assay for Non-Small Cell Lung Carcinoma (NSCLC) P/N 1012345 for examples of acceptable staining performance.

PERFORMANCE CHARACTERISTICS

Specificity/Sensitivity

Analytical specificity and sensitivity were determined by staining multiple cases of normal and neoplastic human tissue with the VENTANA ALK (D5F3) CDx Assay. The results are listed in Table 4 and Table 5.

Table 4. Specificity/Sensitivity of VENTANA ALK (D5F3) CDx Assay in Normal Tissue. Testing used FFPE normal tissues.

Tissue	# Positive / Total Cases	Tissue	# Positive / Total Cases
Cerebrum	0/3*	Thymus	0/3
Cerebellum	0/3	Myeloid (bone marrow)	0/3
Adrenal gland	0/3	Lung	0/3
Ovary	0/3	Heart	0/3
Pancreas	0/3	Esophagus	0/3
Parathyroid gland	0/3	Stomach	0/3
Hypophysis	0/3**	Small intestine	0/3***
Testis	0/3	Colon	0/3***

Tissue	# Positive / Total Cases	Tissue	# Positive / Total Cases
Thyroid	0/3	Liver	0/3
Breast	0/3	Salivary gland	0/3
Spleen	0/3	Kidney	0/3
Tonsil	0/3	Prostate	0/3
Endometrium	0/3	Cervix	0/3
Skeletal muscle	0/4	Skin	0/3
Nerve (sparse)	0/3	Mesothelium and lung	0/3

*2/3 A few glial cells in the cerebrum showed weak-to-moderate positivity.

**3/3 Hypophysis stained weakly.

***Ganglion cells within 4/6 intestinal tissues stained positive for ALK at varying intensities.

Table 5. Specificity/Sensitivity of VENTANA ALK (D5F3) CDx Assay in Neoplastic Tissue. Testing used a variety of formalin-fixed, paraffin-embedded neoplastic tissues.

Tissue	# Positive / Total Cases
Glioblastoma	0/1
Atypical meningioma	0/1
Malignant ependymoma	0/1
Malignant oligodendroglioma	0/1
Serous ovarian adenocarcinoma	1/1
Ovarian adenocarcinoma	0/1
Islet cell carcinoma	0/1
Pancreatic adenocarcinoma	0/1
Seminoma	0/1
Embryonal carcinoma	0/1
Medullary carcinoma	0/1
Papillary carcinoma	0/1
Breast intraductal carcinoma	0/1
Breast invasive ductal carcinoma	0/2
Diffuse B-cell lymphoma	0/3
Lung small cell undifferentiated carcinoma	0/1
Lung squamous cell carcinoma	0/1
Lung adenocarcinoma	0/1
Esophageal squamous cell carcinoma	0/1
Esophageal adenocarcinoma	0/1
Gastric mucinous adenocarcinoma	0/1
Gastrointestinal adenocarcinoma	0/1
Malignant interstitialoma	0/1
Rectal adenocarcinoma	0/1

Tissue	# Positive / Total Cases
Rectal malignant interstitialoma	0/1
Hepatocellular carcinoma	0/1
Hepatoblastoma	1/1
Renal clear cell carcinoma	0/1
Prostatic adenocarcinoma	0/2
Leiomyoma	0/1
Endometrial adenocarcinoma	0/1
Endometrial clear cell carcinoma	0/1
Uterine squamous cell carcinoma	0/2
Embryonal rhabdomyosarcoma	0/1
Anal malignant melanoma	0/1
Basal cell carcinoma	0/1
Squamous cell carcinoma	0/1
Neurofibroma	0/1
Retroperitoneal neuroblastoma	1/1
Malignant mesothelioma	0/1
Hodgkin lymphoma	0/1
Anaplastic large cell lymphoma	0/1
Bladder transitional cell carcinoma	0/1
Low grade leiomyosarcoma	0/1
Osteosarcoma	0/1
Spindle cell rhabdomyosarcoma	0/1
Intermediate grade leiomyosarcoma	0/1

Tissue Thickness

Tissue thickness was evaluated using 4 unique cases of human NSCLC (3 ALK-positive and 1-ALK negative) and 4 unique cases of human appendix. Tissues were sectioned and tested in duplicate at 3, 4, 5, 6, and 7 microns. All tissue thicknesses demonstrated appropriate specific staining for ALK and appropriate background levels with VENTANA ALK (D5F3) CDx Assay. No specimens exhibited a change in clinical ALK status within this range of thickness. Ventana recommends that specimens be cut at 4–6 microns for the assay.

Repeatability and Intermediate Precision Studies

The repeatability and intermediate precision of the VENTANA ALK (D5F3) CDx Assay was evaluated on the BenchMark XT instrument in combination with the OptiView DAB Detection and OptiView Amplification kits by staining 18 unique cases of human NSCLC and 8 unique cases of human appendix. Two precision studies were performed; one evaluated precision on NSCLC and one on appendix.

The first study evaluated 10 unique NSCLC tissue specimens (5 ALK-positive and 5 ALK-negative). For Intra-Day precision, 5 replicate slides from each of the NSCLC specimens were stained on a single BenchMark XT instrument. For Inter-Instrument precision testing, 3 replicate slides from each of the NSCLC specimens were stained with VENTANA ALK (D5F3) CDx Assay across three BenchMark XT automated staining instruments. For Inter-Day precision, 2 replicate slides from each of the NSCLC specimens were stained with the VENTANA ALK (D5F3) CDx Assay on a single BenchMark XT instrument across 5 non-consecutive days. All slides were blinded, randomized, and then evaluated by a

pathologist using the VENTANA ALK (D5F3) CDx Assay scoring algorithm (provided in Table 3). Each replicate NSCLC specimen produced equivalent ALK IHC staining results. A summary of the results can be found in Table 6.

In addition, repeatability of the VENTANA ALK (D5F3) CDx Assay staining on human appendix (system-level control) was also evaluated. Eight unique human appendix tissues were used for this study. For Intra-Day precision, 13 replicate slides from two multi-tissue blocks containing 4 appendix specimens were stained on a single BenchMark XT instrument. For Inter-Instrument precision, 5 replicate slides from two multi-tissue blocks containing 4 appendix specimens each were stained with VENTANA ALK (D5F3) CDx Assay across three BenchMark XT automated staining platforms. For Inter-Day precision, 5 replicate slides from each of two multi-tissue blocks containing 4 appendix specimens were stained with the VENTANA ALK (D5F3) CDx Assay on a single BenchMark XT instrument across 5 non-consecutive days. All slides were evaluated by a pathologist using the VENTANA ALK (D5F3) CDx Assay scoring guide for appendix control tissue (provided in Table 2). Each replicate appendix specimen produced equivalent ALK IHC staining results. The overall percent agreement for intra-day and inter-instrument (across 3 instruments) repeatability was 100%, while the inter-day repeatability (across 5 non-consecutive days) was 98%.

Table 6. Repeatability and Intermediate Precision Study 2 of VENTANA ALK (D5F3) CDx Assay on Individual NSCLC Specimens.

NSCLC Tissue Repeatability/Precision	N= Total Slides Evaluated in the Cohort	Overall Percent Agreement for ALK Status (95% CI)
Intra-Day Repeatability	50	100% (97.5-100%)
Inter-Instrument Precision (across 3 instruments)	90	100% (97.9-100%)
Inter-Day Precision (5 non-consecutive days)	100	100% (98.7-100%)

Lot-to-Lot Reproducibility

Lot-to-lot reproducibility of the VENTANA ALK (D5F3) CDx Assay was determined by testing three lots of the VENTANA ALK (D5F3) CDx Assay across 38 unique NSCLC cases (21 ALK-positive specimens (from 18 unique cases) and 20 ALK-negative NSCLC tissue specimens) on the BenchMark XT instrument using the OptiView DAB IHC Detection and OptiView Amplification kits. All cases were stained in duplicate with each of the three lots of primary antibody. Slides were blinded and randomized prior to evaluation for clinical status as determined by the VENTANA ALK (D5F3) CDx Assay scoring algorithm (provided in Table 3) by three pathologists. All three lots of antibody exhibited greater than 90% concordant staining results for ALK status across the 41 NSCLC tissue specimens evaluated. Results are reported as overall percent agreement, average positive agreement, and average negative agreement rates. The overall percent agreement rate between lots was 99.2%; therefore, the VENTANA ALK (D5F3) CDx Assay is reproducible in its staining results across antibody lots. Results can be found in Table 7.

Lot-to-lot reproducibility of VENTANA ALK (D5F3) CDx Assay was also evaluated using 12 unique human appendix tissue specimens. Reproducibility was determined by testing three lots of antibody in combination with three lots of OptiView DAB IHC Detection and OptiView Amplification Kits across three BenchMark XT automated slide stainers. The overall agreement rate for appropriate positive and negative staining elements of the appendix using VENTANA ALK (D5F3) CDx Assay was 100%.

Table 7. Lot-to-Lot Reproducibility Agreement Rates across 41 NSCLC Tissue Specimens. Twenty-one ALK-positive specimens (from 18 unique cases) and 20 ALK-negative specimens were tested.

Lot –to-Lot Reproducibility Agreement Rates	Average Positive Agreement (95% CI)	Average Negative Agreement (95% CI)	Overall Percent Agreement (95% CI)
Average of all three lot to lot comparisons	99.2% (97.4-100%)	99.1% (96.8-100.0)	99.2% (97.5-100%)

Inter-Reader Precision Studies

Two inter-reader precision studies were performed. In the first study, three pathologists evaluated a total of 185 unique cases. The 185 cases correlated with 100 ALK-positive and 100 ALK-negative blocks that were stained with VENTANA ALK (D5F3) CDx Assay. The cases were blinded and randomized prior to evaluation for ALK IHC staining results per the VENTANA ALK (D5F3) CDx Assay scoring algorithm provided in Table 3. The results provided in Table 8 below reflect the inter-reader precision rates for unique cases from the study cohort.

Table 8. Inter-Reader Precision Study Results—Study 1

Inter-Reader Precision	Average Positive Agreement (95% CI)	Average Negative Agreement (95% CI)	Overall Percent Agreement (95% CI)
Average of all three readers comparisons	98.8% (97.3-100%)	99.0% (97.7-100%)	98.9% (97.4-100%)

The second Inter-Reader Precision Study was evaluated on a cohort of cases from a randomized clinical study of ALK positive NSCLC patients enrolled with the Abbott Vysis ALK Break Apart FISH Probe Kit. Approximately 300 cases were stained with the VENTANA ALK (D5F3) CDx Assay. The cases were blinded for ALK FISH status, randomized, and provided to three readers, who evaluated the ALK IHC staining results per the VENTANA ALK (D5F3) CDx Assay scoring algorithm provided in Table 3. The results provided in Table 9 reflect the inter-reader precision rates from this clinical trial cohort.

Table 9. Inter-Reader Precision Study 2 for ALK status in NSCLC specimens obtained from clinical method comparison Cohort # 1.

Inter-Reader Precision	Average Positive Agreement (95% CI)	Average Negative Agreement (95% CI)	Overall Percent Agreement (95% CI)
Average of all three readers comparisons	97.6% (95.0-99.5%)	99.5% (98.9-99.9%)	99.1% (98.2-99.8%)

Inter-Laboratory Reproducibility Study

An Inter-Laboratory Reproducibility Study for VENTANA ALK (D5F3) CDx Assay was completed to demonstrate reproducibility of the assay in determining ALK clinical status, using NSCLC (6 ALK-positive and 6 ALK-negative) tissue specimens run across three reagent lots, three instruments and 5 non-consecutive days at three external laboratories. The specimens were randomized and evaluated by a total of 6 readers (2 readers/site) who were blinded to the ALK clinical status of the cohort. This cohort contained 180 slides generated from 12 NSCLC cases positive and negative for ALK expression by IHC and FISH. These cases were stained in replicate over 21 days at the three laboratories. See Table 10 for results. The acceptability rate for morphology and background in these studies was 100%. The data indicate excellent agreement in assay reproducibility across 3 sites and 6 readers.

Table 10. Inter-Laboratory Reproducibility: Agreement Rates for VENTANA ALK (D5F3) CDx Assay (n = 180 slides evaluated).

Agreement Rates for Inter-Laboratory Reproducibility (ALK Clinical Status)	Average Positive Agreement (95% CI)	Average Negative Agreement (95% CI)	Overall Percent Agreement (95% CI)
Between-site (3 sites)	93.8% (76.2-100%)	94.9% (79.2-100%)	94.4% (83.3-100%)
Between-day (5 non-consecutive days)	99.1% (96.4-100%)	99.2% (96.9-100%)	99.2% (97.5-100%)
Between-reader (2 readers/site)	98.8% (95.2-100%)	99.0% (95.8-100%)	98.9% (96.7-100%)

Method Comparison Study

The Method Comparison Study cohorts were generated from two independent, randomized clinical trials (designated Trial #1 and Trial #2) that enrolled patients with ALK-positive NSCLC. ALK status for these patients was determined using the Vysis ALK Break Apart FISH Probe Kit clinical trial assay at multiple central laboratories. Valid Vysis ALK FISH results were obtained for a total of 1644 NSCLC tissue specimens (1018 and 626 specimens for Trials #1 and #2, respectively).

In the VENTANA ALK (D5F3) CDx Assay Method Comparison Study, specimens from patients screened for Trials #1 and #2 were sent to a central laboratory for staining with the VENTANA ALK (D5F3) CDx Assay and evaluation for ALK IHC status based on the VENTANA ALK (D5F3) CDx Assay Scoring Algorithm criteria (Table 3). Of the specimens yielding valid Vysis ALK FISH results in clinical trial screening, 933 specimens from Trial #1 (Table 11) and 598 specimens from Trial #2 (Table 13) also yielded valid results for the VENTANA ALK (D5F3) CDx Assay.

The numbers of specimens yielding ALK-positive and ALK-negative results for each assay are shown in Tables 11 and 13 for the Trial #1 and #2 cohorts, respectively. The agreement rates between the two assays are shown in Tables 12 and 14 for the Trial #1 and #2 cohorts, respectively. The reported positive and negative percent agreement rates were 86.0% and 96.3%, respectively, for Trial #1 (Table 12) and 92.7% and 94.8%, respectively, for Trial #2 (Table 14).

Table 11. ALK Status Comparison in NSCLC Specimens (Cohort from Trial #1) Determined Using VENTANA ALK (D5F3) CDx Assay vs. Vysis ALK Break Apart FISH Probe Kit.

ALK Status		Vysis ALK Break Apart FISH Probe Kit		
		Positive	Negative	Total
VENTANA ALK (D5F3) CDx Assay	Positive	154	28	182
	Negative	25	726	751
	Total	179	754	933

Table 12. Agreement Rates between VENTANA ALK (D5F3) CDx Assay and Vysis ALK Break Apart FISH Probe Kit in Trial #1.

Agreement Rates between ALK Assays	Positive Percent Agreement (95% CI)	Negative Percent Agreement (95% CI)	Overall Percent Agreement (95% CI)
VENTANA ALK (D5F3) CDx Assay and Vysis ALK Break-Apart FISH Probe Kit	86.0% (80.2-90.4%)	96.3% (94.7-97.4%)	94.3% (92.6-95.6%)

Table 13. ALK Status Comparison Cohort from Trial #2 in NSCLC Specimens Determined Using VENTANA ALK (D5F3) CDx Assay vs. Vysis ALK Break Apart FISH Probe Kit.

ALK Status		Vysis ALK Break Apart FISH Probe Kit		
		Positive	Negative	Total
VENTANA ALK (D5F3) CDx Assay	Positive	179	21	200
	Negative	14	384	398
	Total	193	405	598

Table 14. Agreement Rates between VENTANA ALK (D5F3) CDx Assay and Vysis ALK Break Apart FISH Probe Kit in Trial #2.

Agreement Rates between ALK Assays	Positive Percent Agreement (95% CI)	Negative Percent Agreement (95% CI)	Overall Percent Agreement (95% CI)
VENTANA ALK (D5F3) CDx Assay and Vysis ALK Break Apart FISH Probe Kit	92.7% (88.2-95.6%)	94.8% (92.2-96.6%)	94.1% (92.0-95.8%)

Note that tissue specimens used in Trial #1 and Trial #2 were not verified as having been prepared according to the specimen preparation procedures recommended for VENTANA ALK (D5F3) CDx Assay.

Clinical Outcome Study

The Clinical Outcome Study was based on Trial #1. These patients were tested with VENTANA ALK (D5F3) CDx Assay under the Method Comparison Study as well as an additional study. Trial #1 was a multicenter, multinational, randomized, open-label, Phase 3 efficacy and safety study of crizotinib vs. first-line chemotherapy (pemetrexed/cisplatin or pemetrexed/carboplatin) in previously untreated patients with ALK-positive advanced non-squamous NSCLC. The Vysis ALK Break Apart FISH Probe Kit (ALK FISH) was used to determine ALK positivity and trial eligibility for Trial #1. Based on the Vysis ALK FISH assay results, 343 patients were in the randomized set (172 in the crizotinib arm and 171 in the chemotherapy arm). In the VENTANA ALK (D5F3) CDx Assay Clinical Outcome Study, tissue specimens from Trial #1 were retrospectively tested with the VENTANA ALK (D5F3) CDx Assay. Of the 343 patients enrolled in Trial #1, 133 had been tested with the VENTANA ALK (D5F3) CDx Assay under the Method Comparison Study protocol, and an additional 39 patients had been tested under a separate study protocol, for a total of 172 patients tested with the VENTANA ALK (D5F3) CDx Assay. Of these patients, 166 were diagnosed as ALK-positive or ALK-negative by ALK (D5F3) IHC. The overall efficacy results for these patients are summarized according to the VENTANA ALK (D5F3) CDx Assay results in Table 15.

Table 15. Clinical Benefit for Patients Enrolled in Trial #1.

ALK Status		HR [a]	SE [a]	95% CI [a]	Sample Size	
					Chemotherapy Arm	Crizotinib Arm
Total Enrolled	FISH+	0.454	0.139	(0.346, 0.596)	171	172
	FISH+/IHC-	0.407	0.214	(0.267, 0.618)	82	90
ALK IHC Tested	FISH+/IHC+	0.401	0.237	(0.252, 0.639)	63	78
	FISH+/IHC-	1.711	0.703	(0.431, 6.789)	17	8

[a] Hazard ratio (HR) of crizotinib versus chemotherapy; SE, standard error; and 2-sided 95% confidence interval. Results were estimated using a stratified Cox model with the following stratum: race, brain metastasis, and ECOG score.

[b] For two ALK FISH+ patients in the chemotherapy arm and 4 patients in the crizotinib arm, no positive or negative ALK IHC result was obtained.

Additional imputation analyses were performed to include patients with missing or invalid VENTANA ALK (D5F3) CDx Assay test results and to evaluate the robustness of study conclusions. Statistical analysis of discordant patients not enrolled in Trial #1 involved simulation of a range of possible outcomes for these patients. Results from all of the hypothetical analyses were generally similar to those from the primary efficacy analysis.

FISH+/IHC- Discordant Cases from Trial #1:

Method Comparison Study

In the Method Comparison Study (Tables 11 and 12), 25 patients from Trial #1 were evaluated as FISH+/IHC-. The median Vysis ALK FISH score (% tumor cells positive for ALK gene rearrangement) for these cases was 20% (mean 31.6%, SD 21.58%), and for 14 of these cases, the FISH score was 25% or less. While all of these cases had Vysis

ALK FISH scores above the 15% cut-off for ALK positivity, their scores were in the FISH equivocal zone (10%–50%). In contrast, the median FISH score observed for all enrolled patients tested with IHC was 58% (mean 56.9%, SD 21.97%).

Clinical Outcome Study

In the Clinical Outcome Study, 25 patients enrolled into Trial #1 were evaluated as IHC- (see last row of Table 15). Eight of these cases were randomized to the crizotinib arm of the clinical study. Of these patients, five had FISH scores very close to the FISH cut-off (15%–18% of tumor cells positive for ALK gene rearrangement) and also exhibited objective progression or stable disease/no response. Two of the 8 patients had FISH scores outside the FISH equivocal zone (66% and 72% of tumor cells positive for ALK gene rearrangement) and exhibited a partial objective tumor response. The eighth IHC-patient was FISH- and was enrolled erroneously; this patient exhibited an indeterminate response.

FISH-/IHC+ Discordant Cases from Trial #1

In the VENTANA ALK (D5F3) CDx Assay Method Comparison Study, 28 cases screened for Trial #1 were evaluated as FISH-/IHC+. Since FISH was the clinical trial assay, and only FISH+ cases were enrolled into Trial #1, no outcome data are available on the FISH-/IHC+ discordant cases.

Conclusion

VENTANA ALK (D5F3) CDx Assay is reproducible in its staining results for clinical ALK status on the BenchMark XT instrument. The binary scoring algorithm is highly reproducible across readers. The assay is concordant with Vysis ALK Break Apart FISH Probe Kit for ALK status. VENTANA ALK (D5F3) CDx Assay may be used in identifying patients eligible for treatment with XALKOR[®] (crizotinib).

REFERENCES

- Kutok JL, Aster JC, et al. Molecular biology of anaplastic lymphoma kinase-positive anaplastic large-cell lymphoma. *J Clin. Onc.* 2002;20(17):3691-3702.
- Iwahara T, et al. Molecular characterization of ALK, a receptor tyrosine kinase expressed specifically in the nervous system. *Oncogene.* 1997;14:439-49.
- Soda M, et al. Identification of the transforming EML4-ALK fusion gene in non-small-cell lung cancer. *Nature* 2007;448(7153):561-66.
- Inamura K, et al. EML4-ALK fusion is linked to histological characteristics in a subset of lung cancers. *J Thorac Oncol.* 2008;3(1):13-17.
- Choi YL, et al. Identification of novel isoforms of the EML4-ALK transforming gene in non-small cell lung cancer. *Cancer Res.* 2008;68(13):4971-76.
- Koivunen JP, et al. EML4-ALK fusion gene and efficacy of an ALK kinase inhibitor in lung cancer. *Clin Cancer Res.* 2008;14(13):4275-83.
- Shimura K, et al. EML4-ML4-ALK fusion transcripts, but no NPM-, TPM3-, CLTC-, ATIC-, or TFG-ALK fusion transcripts, in non-small cell lung carcinomas. *Lung Cancer.* 2008;61:163-9.
- Takeuchi K, et al. Multiplex reverse transcription-PCR screening for EML4-ALK fusion transcripts. *Clin Cancer Res.* 2008;14(20):6618-24.
- Shaw AT, et al. Clinical features and outcome of patients with non-small-cell lung cancer who harbor EML4-ALK. *J Clin Oncol.* 2009;27(26):4247-53.
- Yi ES, et al. Correlation of IHC and FISH for ALK gene rearrangement in non-small cell lung carcinoma: IHC score algorithm for FISH. *J Thorac Oncol.* 2011;6(3):459-65.
- McLeer-Florin A, et al. Dual IHC and FISH testing for ALK gene rearrangement in lung adenocarcinomas in a routine practice: a French study. *J of Thorac Oncol.* 2012;7(2):348-54.
- Christensen JG, et al. Cytoreductive antitumor activity of PF-2341066, a novel inhibitor of anaplastic lymphoma kinase and c-Met, in experimental models of anaplastic large-cell lymphoma. *Mol Cancer Ther.* 2007;6(12 Pt 1):3314-22.
- Yamazaki S, et al. Pharmacokinetic/pharmacodynamic modeling of crizotinib for anaplastic lymphoma kinase inhibition and antitumor efficacy in human tumor xenograft mouse models. *J Pharmacol Exp Ther.* 2012;340(3):549-57.
- Xalkori package insert. Pfizer. Document ID:6427427a-821b-48b4-8f06-0477f0ae4e36. LAB-0441-6.0.June 2014.
- Galetta D, et al. The emerging role of ALK inhibitors in the treatment of advanced non-small cell lung cancer. *Expert Opin Ther Targets.* 2012 Suppl 2: SS45-54.
- Jokoji R, et al. Combination of morphological feature analysis and immunohistochemistry is useful for screening of EML4-ALK-positive lung adenocarcinoma. *J Clin Pathol.* 2010;63(12):1066-70.

17. Mino-Kenudson M, et al. A novel, highly sensitive antibody allows for the routine detection of ALK-rearranged lung adenocarcinomas by standard immunohistochemistry. *Clin Cancer Res.* 2010;16(5):1561-71.
18. Sheehan DC, Hrapchak BB. *Theory and Practice of Histotechnology*, 2nd edition. St. Louis: C.V. Mosby Company; 1980.
19. Carson F, Hladik C. *Histotechnology: A Self Instructional Text*, 3rd edition. Hong Kong: American Society for Clinical Pathology Press; 2009.
20. NordiQC: Nordic Immunohistochemical Quality Control Anaplastic Lymphoma Kinase (ALK) (lung protocol). Assessment Run 39 2013. http://www.nordiqc.org/Run-39-B16-H4/Assessment/Run39_ALK.pdf. 07-12-2013. Accessed February 26, 2014.
21. College of American Pathologists Laboratory Accreditation Program, Anatomic Pathology Checklist, 2011.
22. CLSI. *Quality Assurance for Design Control and Implementation of Immunohistochemistry Assays: Approved Guideline-Second Edition*. CLSI document I/LA28-A2 (ISBN 1-56238-745-6). CLSI, 940 West Valley Road, Suite 1400, Wayne, PA 19087-1898 USA, 2011.
23. Herman GE, Elfont EA. The taming of immunohistochemistry: the new era of quality control. *Biotech Histochem.* 1991;66(4):194-99.
24. Omata M, et al. Nonimmunologic binding of horseradish peroxidase to hepatitis B surface antigen. A possible source of error in immunohistochemistry. *Am J Clin Pathol.* 1980;73(5):626-32.
25. Nadji M, Morales AR. Immunoperoxidase: part 1. The technique and its pitfalls. *Lab Med.* 1983;14:767.

INTELLECTUAL PROPERTY

BENCHMARK, OptiView, VENTANA, and the VENTANA logo are trademarks of Roche.

All other trademarks are the property of their respective owners.

© 2015 Ventana Medical Systems, Inc.

Sold under license from



CONTACT INFORMATION



Ventana Medical Systems, Inc.

1910 E. Innovation Park Drive

Tucson, Arizona 85755

USA

+1 520 887 2155

+1 800 227 2155 (USA)



www.ventana.com

VENTANA ALK (D5F3) CDx Assay Interpretation Guide for Non-Small Cell Lung Carcinoma (NSCLC)

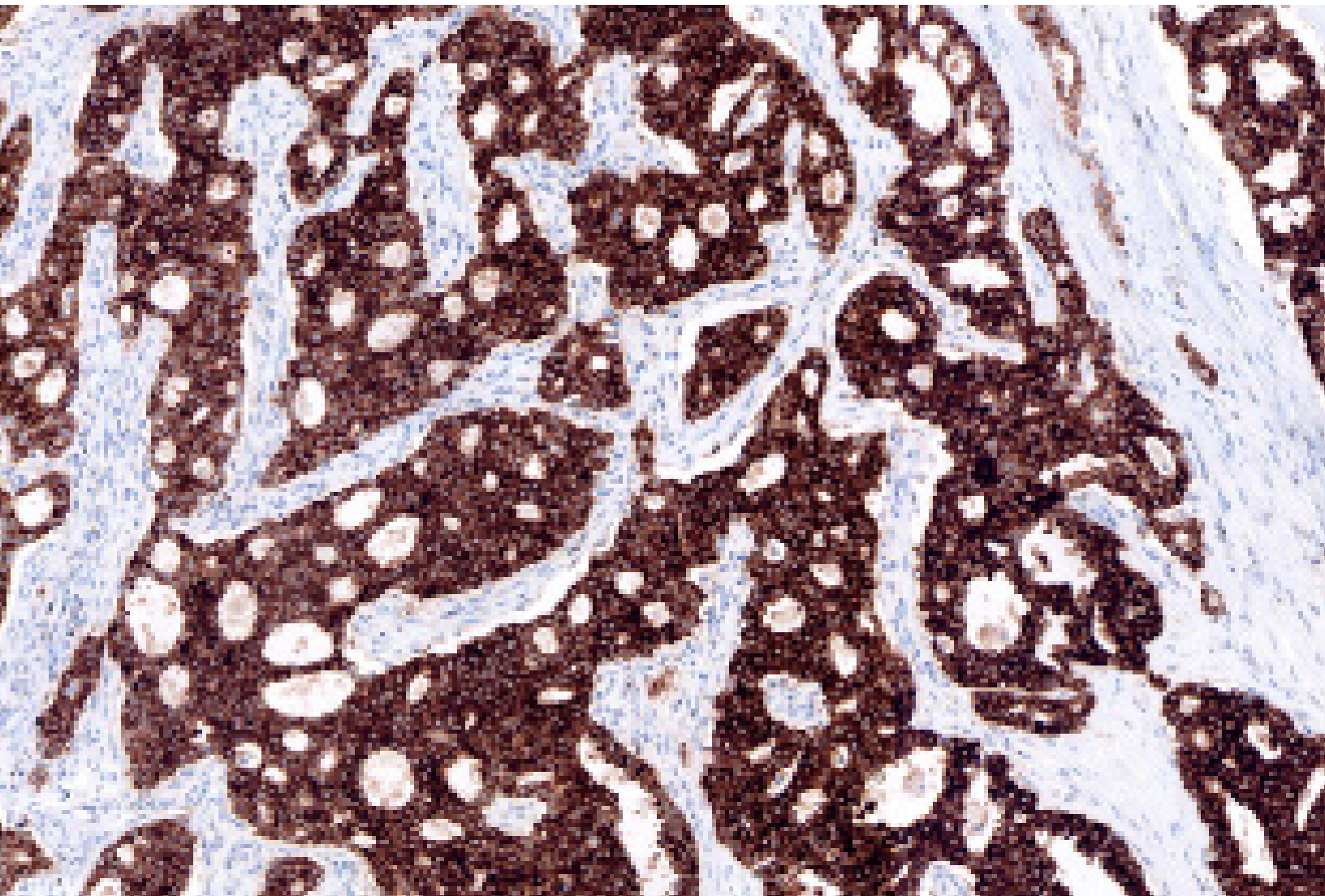


Table of Contents

Introduction	1
Intended Use	3
Intended Use of Product	4
Purpose of Interpretation Guide	4
Clinical Evaluation	5
Specimen Flow	8
System-Level Control	9
Decision Tree	11
Negative Cases	13
Positive Cases	17
Challenging Cases	27
Challenging cases and known staining artifacts	29
Challenging cases: Non-specific background staining	30
Challenging cases: Granular cytoplasmic staining in alveolar macrophages	32
Challenging cases: Granular cytoplasmic staining in scattered lymphoreticular cells within lymphocytic infiltrate	33
Challenging cases: Granular cytoplasmic staining in benign glandular epithelium	33
Challenging cases: Granular cytoplasmic staining in ganglion cells	34
Challenging cases: Strong granular membrane ALK-staining	35
Challenging cases: Mucin staining	36
Challenging cases: DAB Trapping	37
Reproducibility of the VENTANA ALK (D5F3) CDx Assay Staining	37
Pre-analytical conditions and their impact on VENTANA ALK (D5F3) CDx Assay staining	39
Fixative Examples (Xenografts)	40
Examples of the impact of fixation conditions with VENTANA ALK (D5F3) CDx Assay	41
Comparison of IHC lung markers fixed with 10% NBF	42
Cut Slide Stability	43
References	45

Introduction

The anaplastic lymphoma kinase (ALK) protein is a member of the insulin receptor superfamily of receptor tyrosine kinases.¹ ALK is a type I membrane glycoprotein that is normally expressed only in the nervous system.² ALK resides at chromosome 2p23 and is constructed of 2 large introns and 26 exons.¹ The molecular pathogenesis of ALK begins with chromosomal rearrangements that partner the 3' coding sequences for the intracellular signaling domain with 5' promoter elements and coding sequences of other genes.

An inversion within chromosome 2p, resulting in the formation of a fusion gene product comprising portions of the echinoderm microtubule associated protein-like 4 (EML4) gene and the ALK gene, was discovered in 2007 in non-small cell lung carcinoma (NSCLC) cell lines and archived clinical specimens.³ Studies indicated that EML4-ALK inversion events included at least 9 fusion variants, all containing the same portion of the ALK C-terminal kinase domain, rendering them catalytically active.⁴⁻⁸ Consistent with this, EML4-ALK expression in lung alveolar epithelial cells in transgenic mice was a potent oncogenic factor.⁹ The fusion renders ALK in a cytoplasmic localization.

ALK is now recognized as a key oncogenic driver in NSCLC, and although EML4 is the predominant fusion partner, other fusion partner genes have been identified.^{10,11} The incidence of ALK gene rearrangements appears to range from 2-7%, translating to approximately 6,000 ALK positive patients/year in the United States and approximately 40,000 patients/year worldwide.^{3,4,7} However, there are limitations to this estimation, including a small dataset (1,500 tumor samples) and the different ALK methodologies used across studies. Notably, the vast majority of ALK gene rearrangements were observed in lung adenocarcinoma specimens compared with squamous or small cell histologies.³⁻⁸ There is also evidence that ALK gene rearrangements tend to correlate with patients who are of "never or light" smoking status, although this may not be a statistically significant cofactor.^{3,4,7,9} Importantly, ALK gene rearrangements are rarely coincident with EGFR, HER2, or KRAS mutations, demonstrating that ALK positivity is a distinct disease subtype.⁹

Ventana has developed the VENTANA ALK (D5F3) CDx Assay, which is comprised of the VENTANA ALK (D5F3) CDx Assay antibody, the OptiView DAB IHC Detection Kit, and OptiView Amplification Kit, as a fully automated immunohistochemistry (IHC) assay on the BenchMark XT immunohistochemical automated slide stainer. The sensitivity of the IHC assay enables a reproducible, binary scoring system (Positive or Negative for ALK status) for evaluating the staining results (refer to the package insert for VENTANA ALK (D5F3) CDx Assay, Cat. No. 790-4796 / 06687199001). Ventana used a range of human NSCLC tissue specimens in developing the ALK IHC assay from formalin-fixed, paraffin-embedded (FFPE) primary and metastatic NSCLC tumors, such as resection, needle biopsies, bronchial biopsies, and cell blocks from FNA.

Intended Use

Intended Use

Intended Use of product

VENTANA ALK (D5F3) CDx Assay is intended for qualitative detection of the anaplastic lymphoma kinase (ALK) protein in formalin-fixed, paraffin-embedded (FFPE) non-small cell lung carcinoma (NSCLC) tissue stained with a BenchMark XT automated staining instrument. It is indicated as an aid in identifying patients eligible for treatment with XALKORI® (crizotinib).

Assay Interpretation

The clinical interpretation of any staining, or the absence of staining, must be complemented by histological studies and evaluation of proper controls. Evaluation must be made by a qualified pathologist within the context of the patient's clinical history and other diagnostic tests.

This product is intended for *in vitro* diagnostic (IVD) use.

Purpose of Interpretation Guide

This guide is intended to:

- Provide pathologists with a tool to facilitate the clinical evaluation of formalin-fixed, paraffin-embedded (FFPE) NSCLC sections stained with the VENTANA ALK (D5F3) CDx Assay in accordance with the proposed product labeling.
- Provide photographic images that illustrate the staining patterns that may result from staining of NSCLC tissues with the VENTANA ALK (D5F3) CDx Assay.
- Provide example images of challenging cases to provide guidance in their evaluation.
- Provide guidance in using an ALK-positive control tissue (e.g., appendix), which serves as a tissue control when stained with the VENTANA ALK (D5F3) CDx Assay.

Clinical Evaluation

Clinical Evaluation

Evaluating the VENTANA ALK (D5F3) CDx Assay in NSCLC

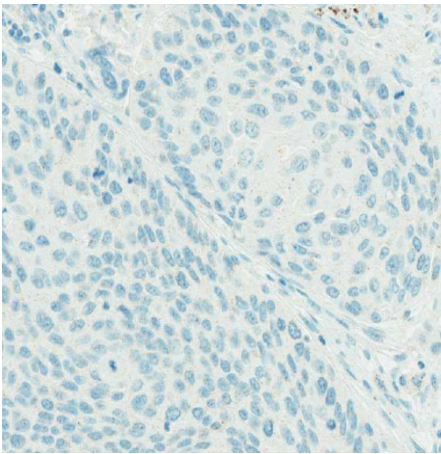
For the VENTANA ALK (D5F3) CDx Assay, each case is stained with the VENTANA ALK (D5F3) CDx Assay and a Rabbit Monoclonal Negative Control Ig antibody. Neoplastic cells labeled with the VENTANA ALK (D5F3) CDx Assay are evaluated for presence or absence of the DAB signal. The matched negative control slide is used to assess non-specific background staining and degree of background staining known to occur due to specific tissue elements (refer to positive and negative case images below). Please note: All cases must be stained with the OptiView DAB IHC Detection Kit and the OptiView Amplification Kit, because some cases are weakly positive for ALK by DAB detection only.

The scoring algorithm for VENTANA ALK (D5F3) CDx Assay is provided below in Table 1. Representative cases are discussed in the images.

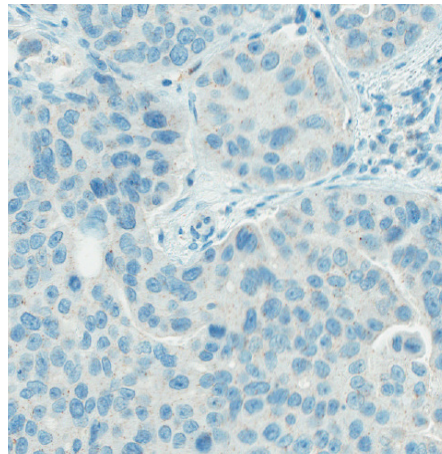
Table 1: Scoring Criteria for Determination of ALK status in NSCLC.

Clinical Interpretation	Staining Description
Positive for ALK	<p>Presence of strong granular cytoplasmic staining in tumor cells (any percentage of positive tumor cells). Certain staining elements should be excluded, including:</p> <ul style="list-style-type: none">▪ light cytoplasmic stippling in alveolar macrophages,▪ cells of neural origin (nerve and ganglion cells),▪ glandular epithelial staining, and▪ scattered lymphoreticular cells within lymphocytic infiltrate. <p>Some background staining also may be observed within normal mucosa in NSCLC (including mucin) and in necrotic tumor areas, which should be excluded from the clinical evaluation.</p>
Negative for ALK	Absence of strong granular cytoplasmic staining in tumor cells.

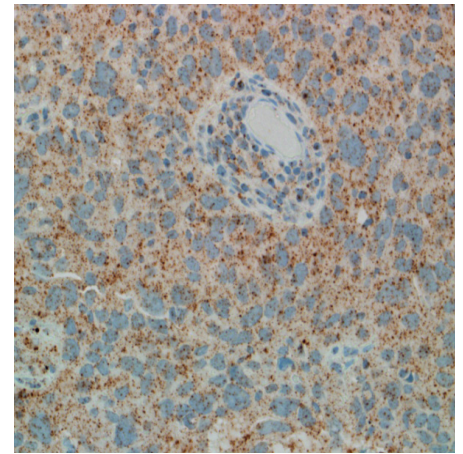
Clinical Diagnosis Negative



No staining

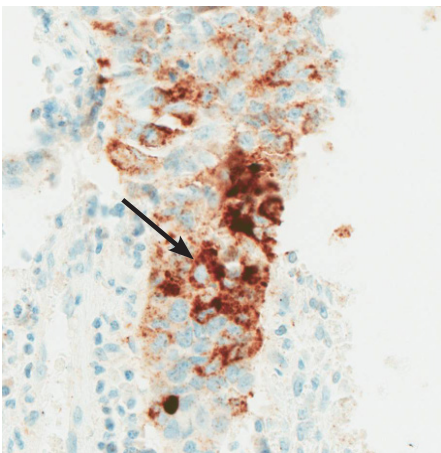


Light speckling in tumor cells

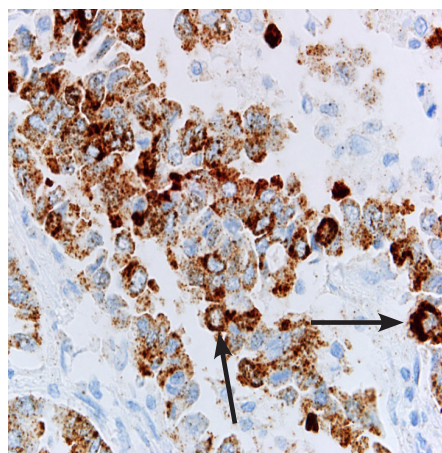


Non-specific diffuse granular staining

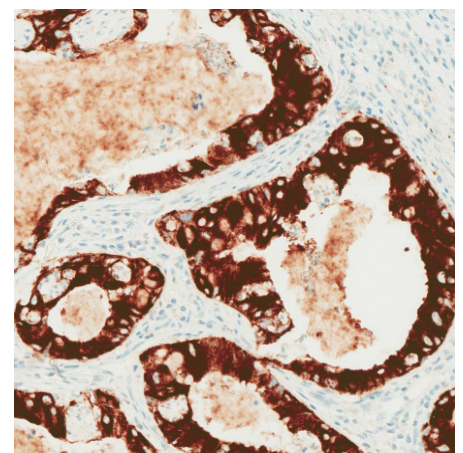
Clinical Diagnosis Positive



Few strong cytoplasmic staining tumor cells



Strong cytoplasmic staining tumor cells

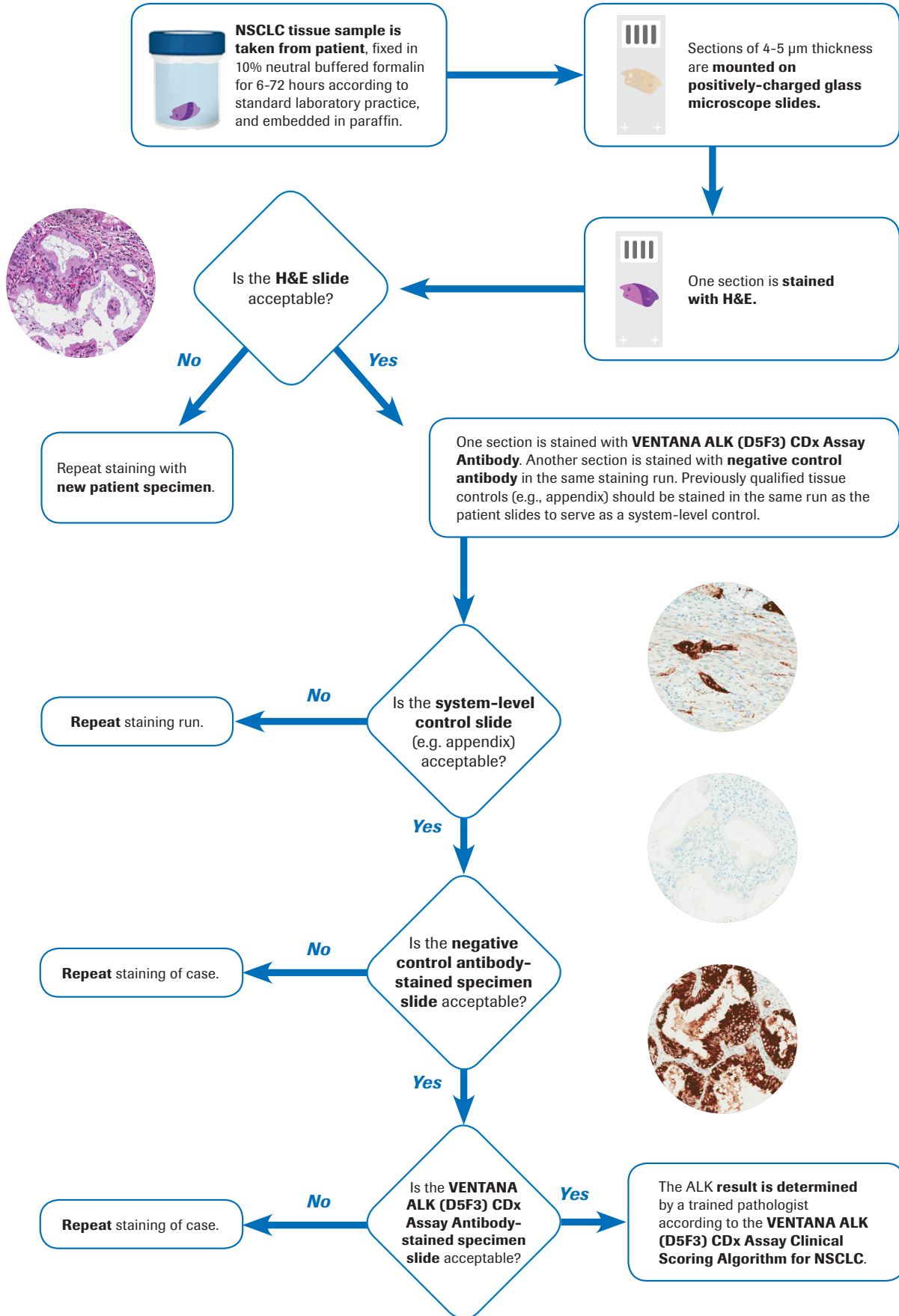


Homogeneously strong cytoplasmic staining within tumor cells

Staining requires three serial sections from each case, one tissue section for hematoxylin and eosin (H&E) staining, a second tissue section for isotype Rabbit Monoclonal Negative Control Ig antibody staining and a third tissue section for VENTANA ALK (D5F3) CDx Assay staining. If the H&E evaluation indicates that the patient specimen is inadequate, then a new specimen should be obtained and stained with the VENTANA ALK (D5F3) CDx Assay.

Pre-qualified NSCLC tissues positive and negative for ALK per the scoring algorithm in Table 1 may be used as system-level run controls. Alternately, pre-qualified appendix tissue exhibiting strong ALK staining of the ganglion cells and absence of strong granular staining in lymphoid, myenteric plexus, and glandular cells of the appendix may also be used as system-level run controls. Both positive and negative elements must be stained appropriately as defined by the scoring algorithm for NSCLC (Table 1) or acceptance criteria for appendix (Table 2) on each run for the run to be considered valid. Specimen slides stained using VENTANA ALK (D5F3) CDx Assay should be assessed by a trained pathologist. If the tissue control slide stained using the VENTANA ALK (D5F3) CDx Assay is not acceptable, staining of patient samples should be repeated. A non-evaluable slide stained using VENTANA ALK (D5F3) CDx Assay would mean that determination of reactivity is not possible due to necrosis, absent tissue, or artifacts.

Specimen Flow



System-Level Control

Either appendix tissue with positive and negative staining elements or ALK-positive and ALK-negative NSCLC tissues are recommended for use as system-level run control tissues. Ganglion cells of the appendix show strong cytoplasmic granular staining for ALK. Additionally, strong cytoplasmic granular staining has also been observed in nerve of the muscular layer of the appendix. Absence of strong granular cytoplasmic staining in glandular epithelial cells, muscle and lymphoid tissue of the appendix (scant or rare staining of lymphoreticular cells may be observed in lymphoid aggregates) should be assessed as negative per the acceptance criteria found in Table 2. ALK-positive and ALK-negative NSCLC tissues sourced for use as system-level run controls should be evaluated based on the ALK Scoring Algorithm for NSCLC found above in Table 1.

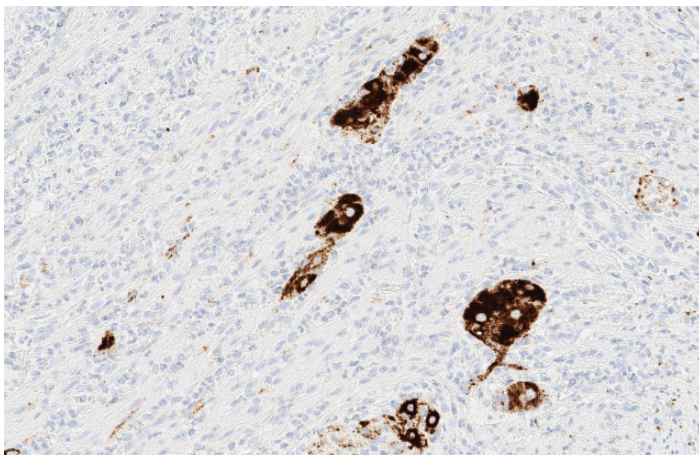
A positive control tissue should be a fresh autopsy/biopsy/surgical specimen that is fixed and processed in the same manner as the patient specimens and should be run for each set of test conditions with every VENTANA ALK (D5F3) CDx Assay performed. This tissue

may be used to monitor all steps of specimen processing and staining. A tissue section fixed or processed differently from the test specimen can be used as a control for reagents and staining but may not be used as a control for fixation or tissue preparation. Positive strong granular cytoplasmic staining of ganglion cells and absence of strong granular cytoplasmic staining in the glandular epithelium, muscle, and lymphoid tissue in the appendix control specimen confirms that VENTANA ALK (D5F3) CDx Assay was applied and the instrument functioned properly. The positive tissue control should only be used to monitor performance and it should not be used to aid the clinical diagnosis of patient samples. In areas of marked inflammation in appendix, an increase in specific staining of neural/neuroendocrine structures and histiocytes in the lymphoid tissue may be observed when stained with the VENTANA ALK (D5F3) CDx Assay. This may be due to reactive hyperplasia of neural structures or drop out of other normal structures due to the inflammation. These structures were confirmed to be neural/neuroendocrine structures and histiocytes by additional antibody stains (S100, Synaptophysin, and CD68).

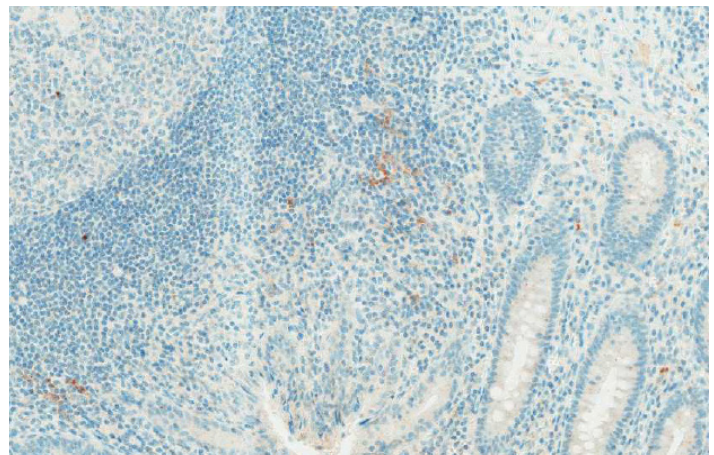
Table 2: Acceptance Criteria for ALK staining in appendix control tissue

Acceptable	Unacceptable
Presence of strong granular cytoplasmic staining in ganglion cells. <i>(See note)</i>	Absence of strong granular cytoplasmic staining in ganglion cells.
Absence of strong granular cytoplasmic staining in glandular epithelial cells, muscle and lymphoid tissue (scant or rare staining of lymphoreticular cells may be observed in lymphoid aggregates).	Excessive non-specific background staining of glandular epithelial cells, muscle, or lymphoid tissue that interferes with scoring.

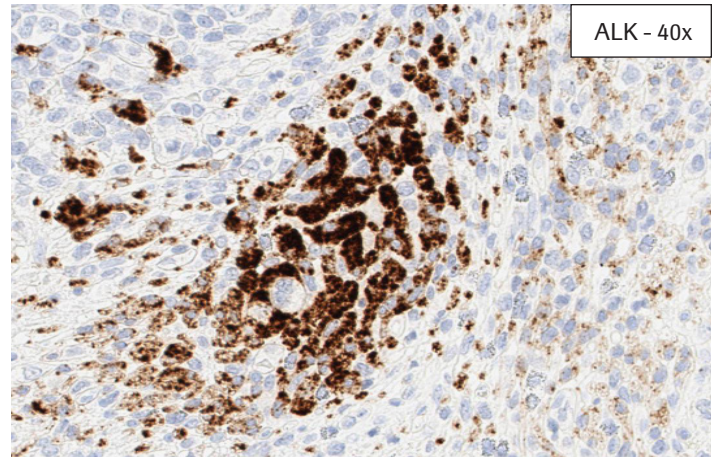
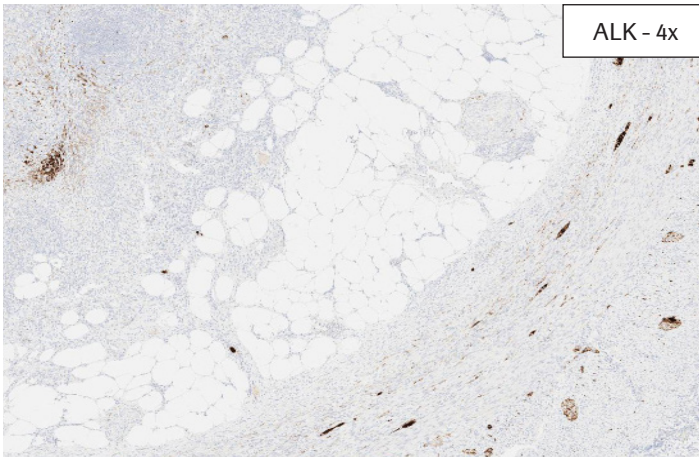
Note: The nerve in appendix muscular layers shows positive staining.



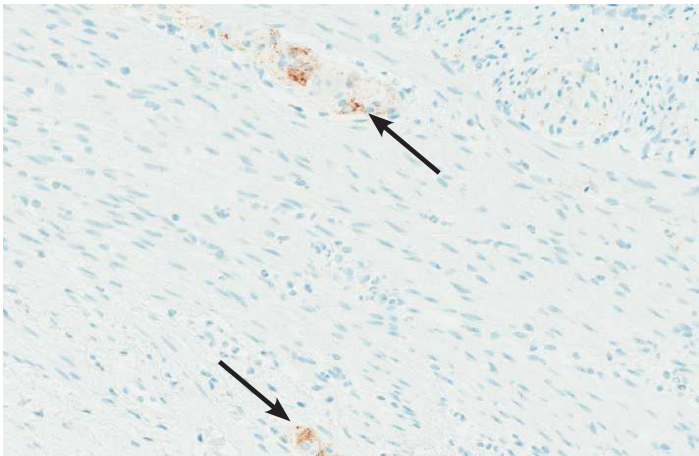
Strong granular cytoplasmic staining on the ganglion cell of the appendix and lack of excessive non-specific staining of the muscle layer. (Acceptable).



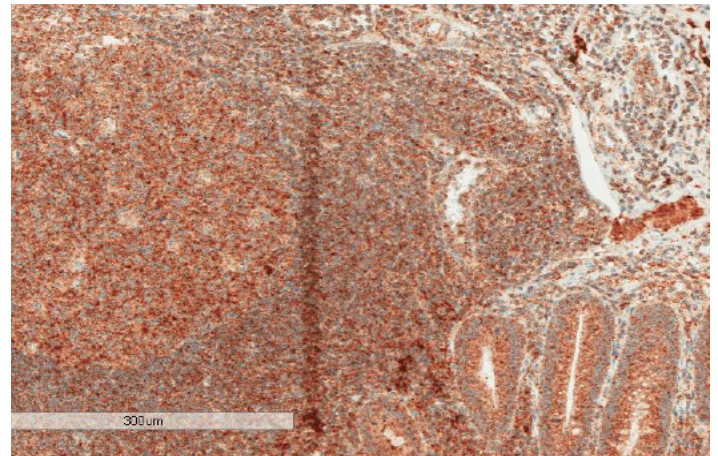
Lack of strong granular cytoplasmic staining in the lymphoid tissue and glandular epithelium (Acceptable).



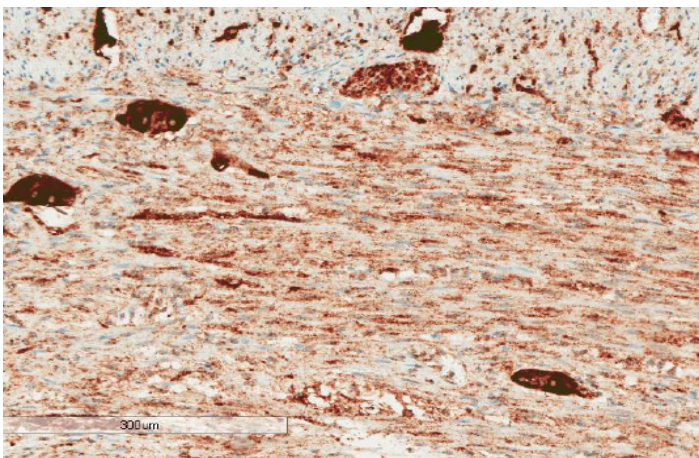
An increase in specific staining of neural structures may be observed in markedly inflamed appendix when stained with the VENTANA ALK (D5F3) CDx Assay. This staining should be excluded when evaluating negative-staining elements of the appendix tissue (Acceptable). Box inset shows area of 40x magnification.



Arrows indicate lack of strong granular cytoplasmic staining of the ganglion cells of the appendix (Not acceptable).



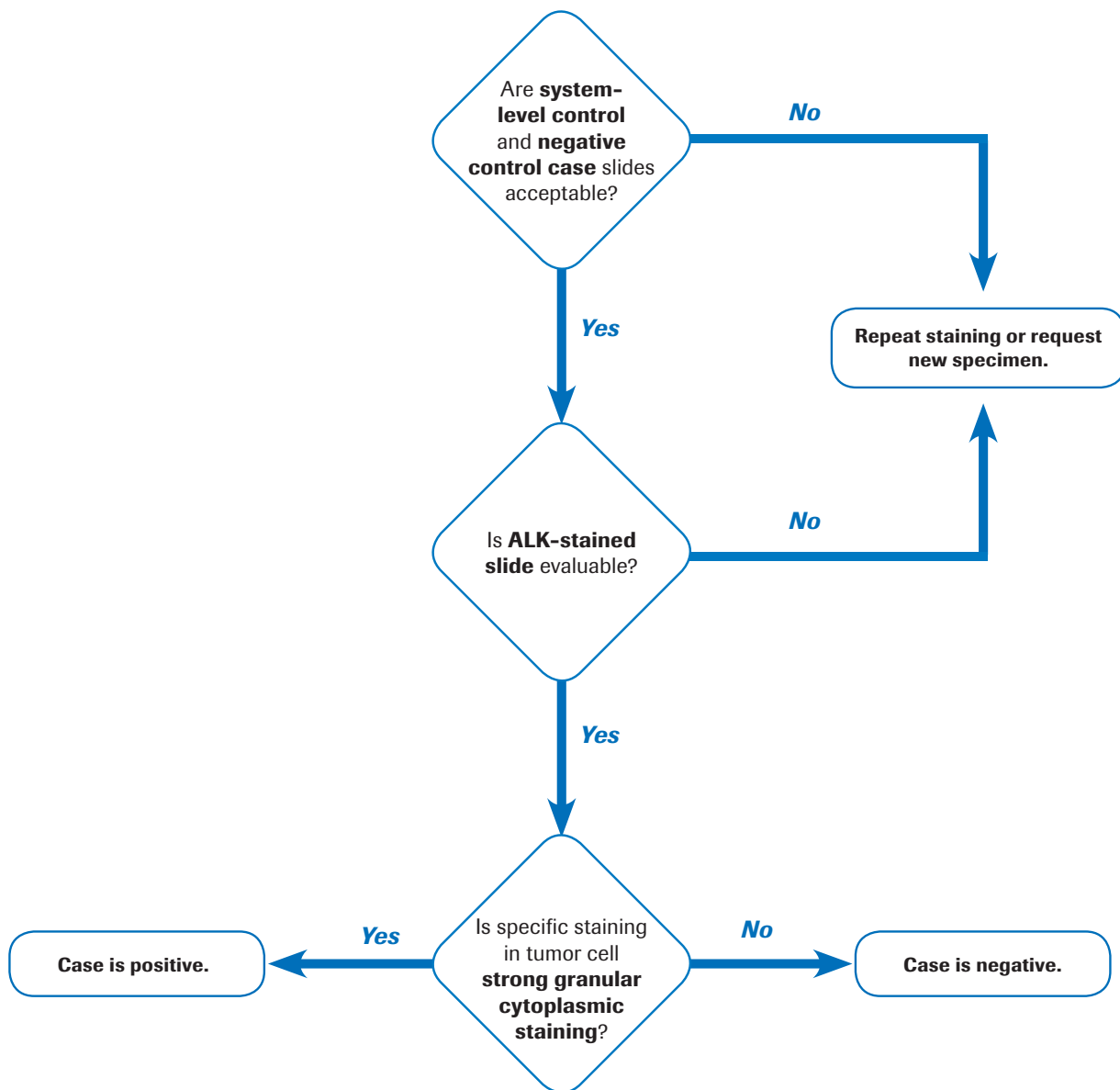
Inappropriate non-specific staining on the lymphoid tissue and glandular epithelium (Not acceptable).



Inappropriate non-specific staining of the muscle layer of the appendix (Not acceptable).

Decision Tree

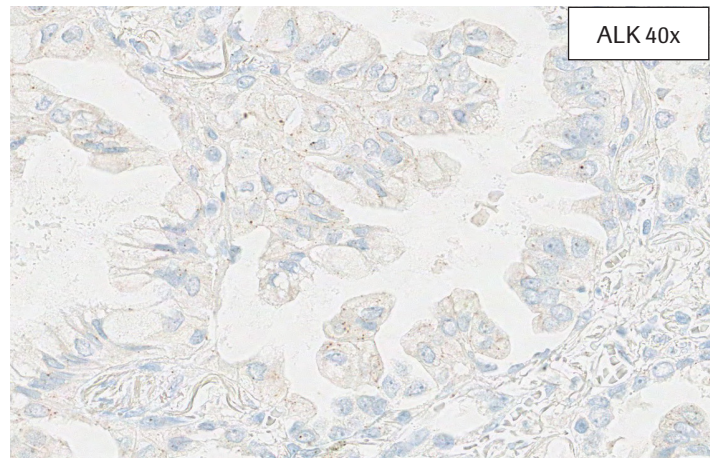
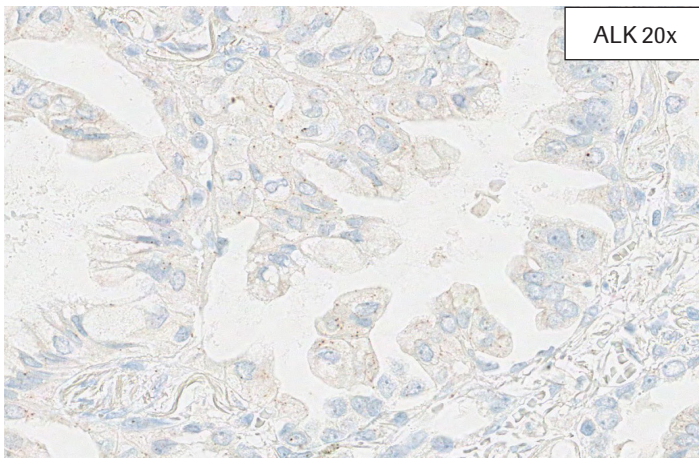
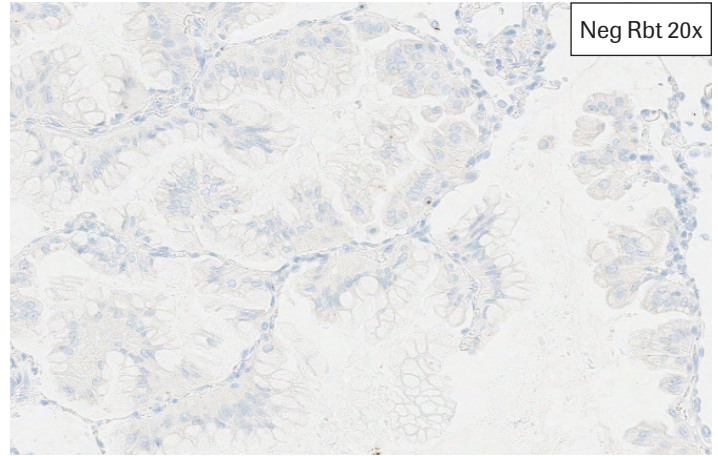
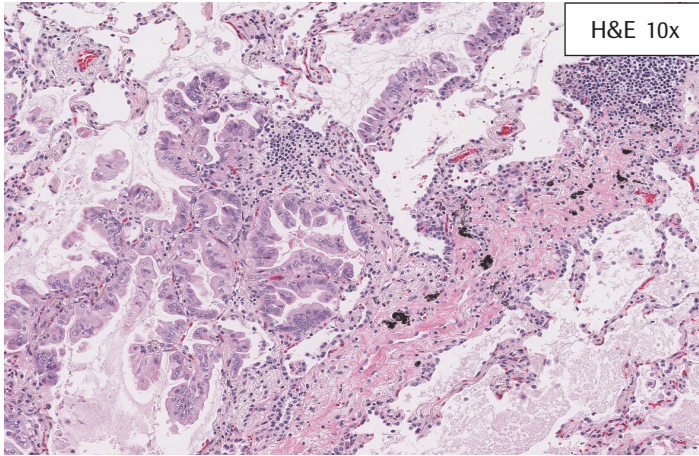
Slides stained with VENTANA ALK (D5F3) CDx Assay should be evaluated using the approach noted in the figure below.



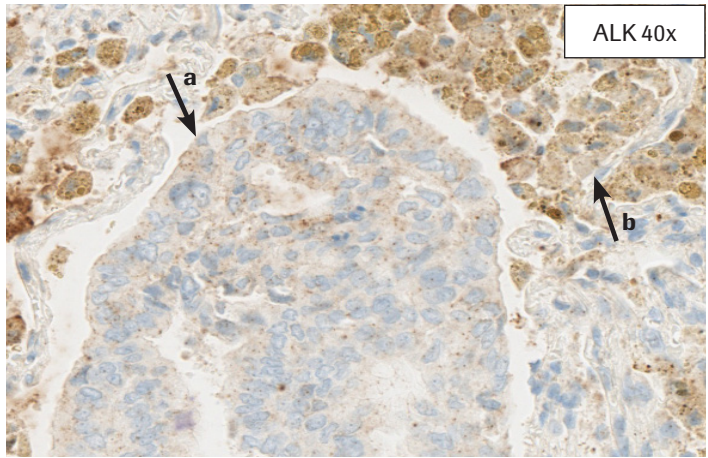
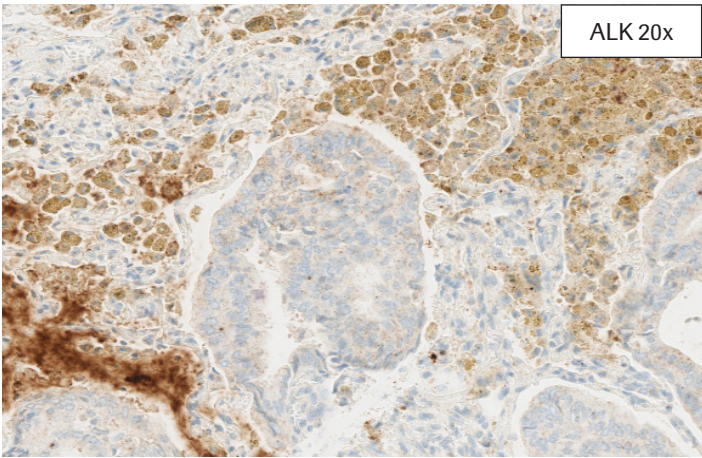
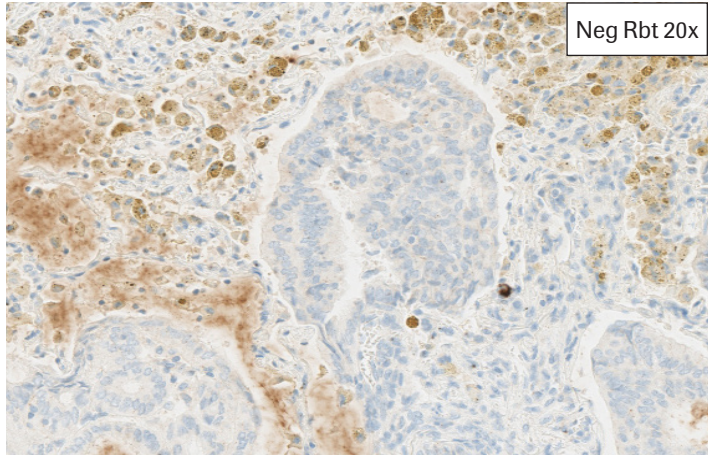
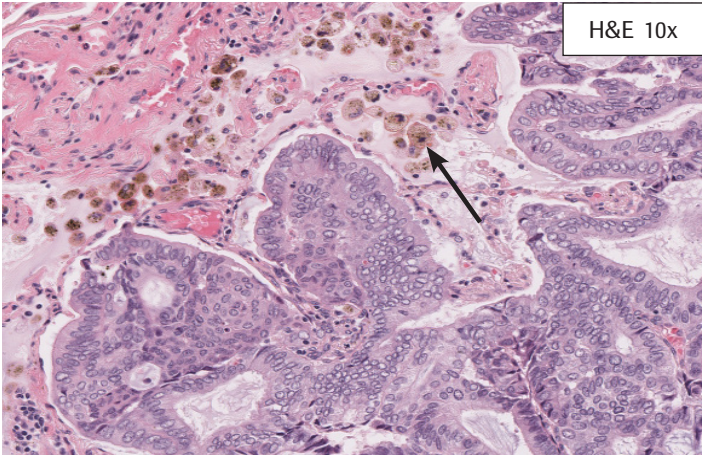
Negative Cases

Negative Cases

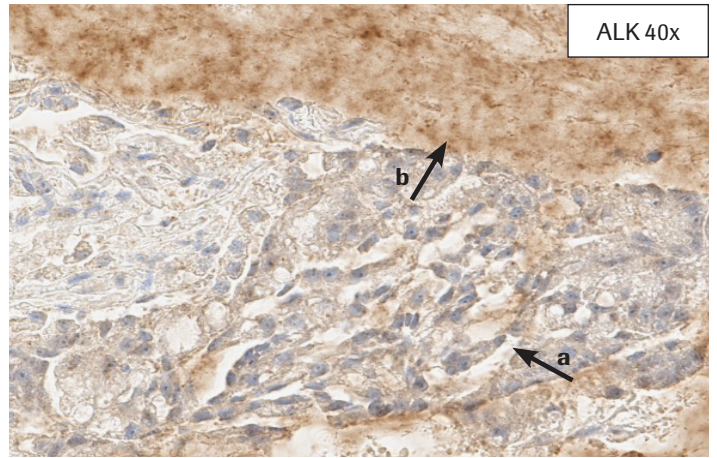
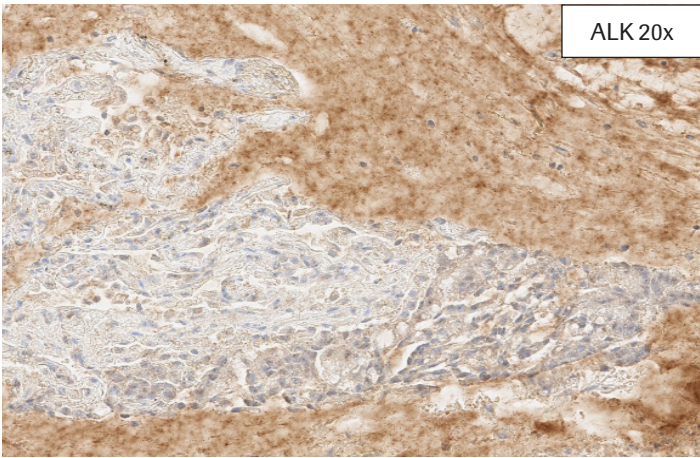
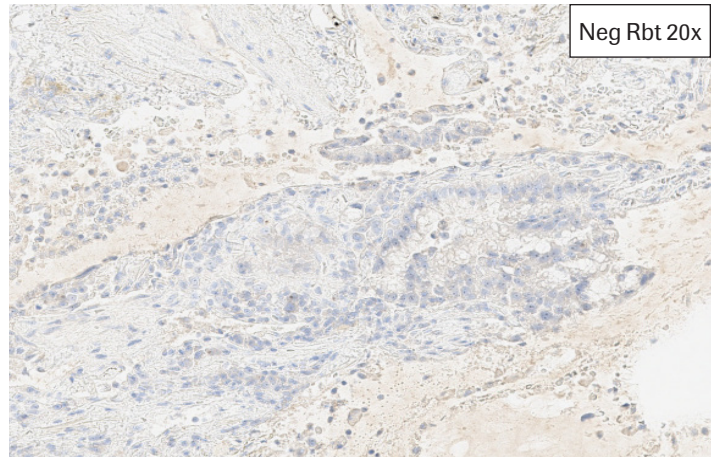
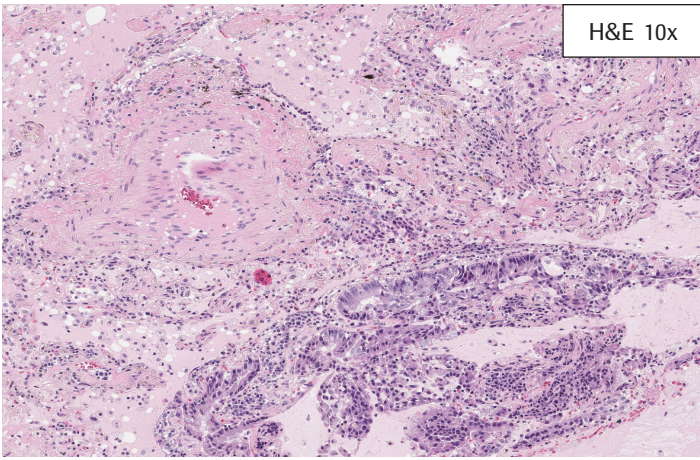
A case is assigned a Negative Clinical Diagnosis for ALK status if no strong granular cytoplasmic staining is observed in any tumor cell.



Negative Case 1 exhibits no detectable ALK staining relative to the negative control antibody-stained slide. This case is assigned a Negative Clinical Diagnosis for ALK status.



Negative Case 2 exhibits non-specific diffuse granular ALK staining in the tumor cells (a) and staining in the alveolar macrophages (b). No strong granular cytoplasmic staining is observed in tumor cells. This case is assigned a Negative Clinical Diagnosis for ALK status.

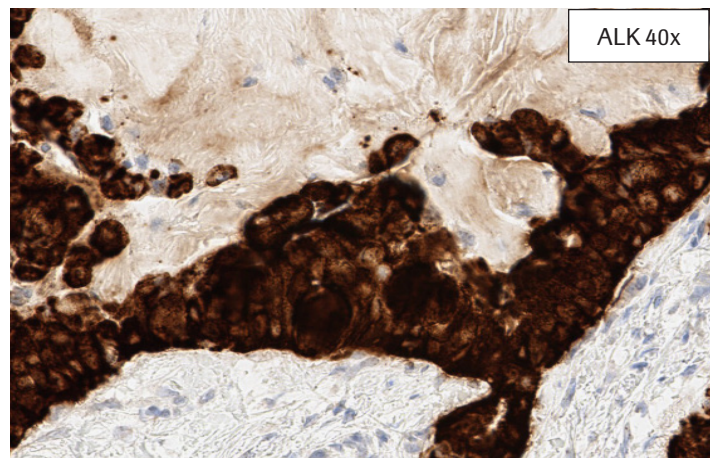
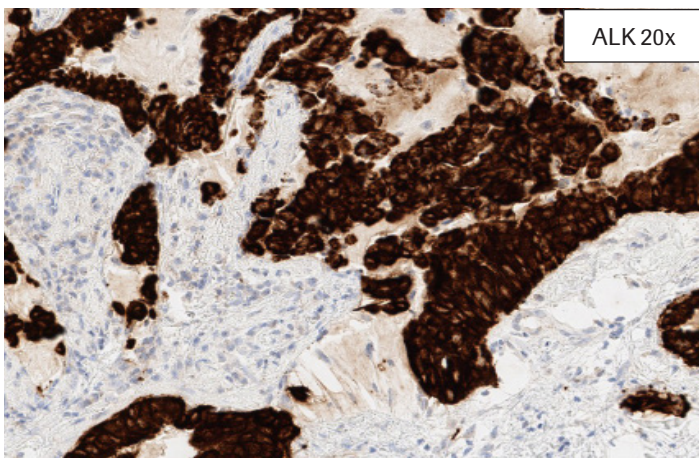
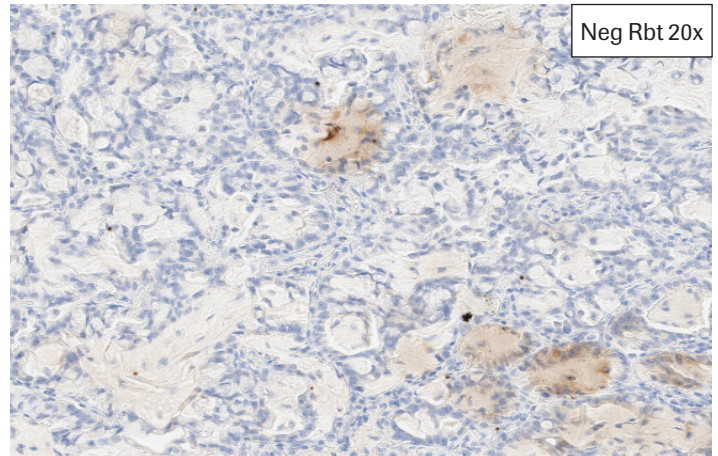
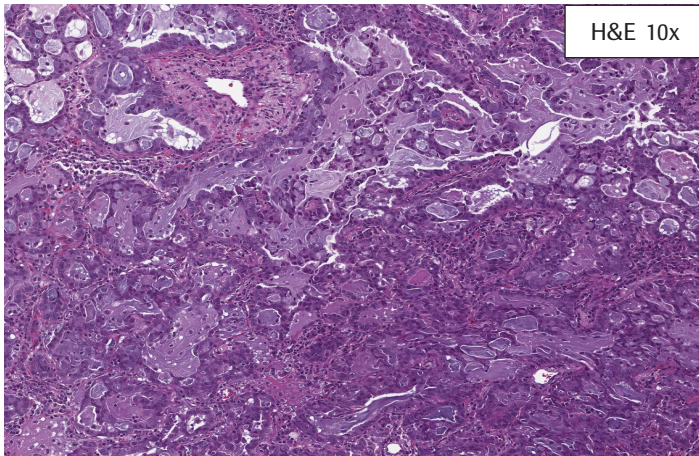


Negative Case 3 exhibits weak cytoplasmic ALK staining in tumor cells (a) and granular non-specific background staining of necrotic tissue (b). This case is assigned a Negative Clinical Diagnosis for ALK status

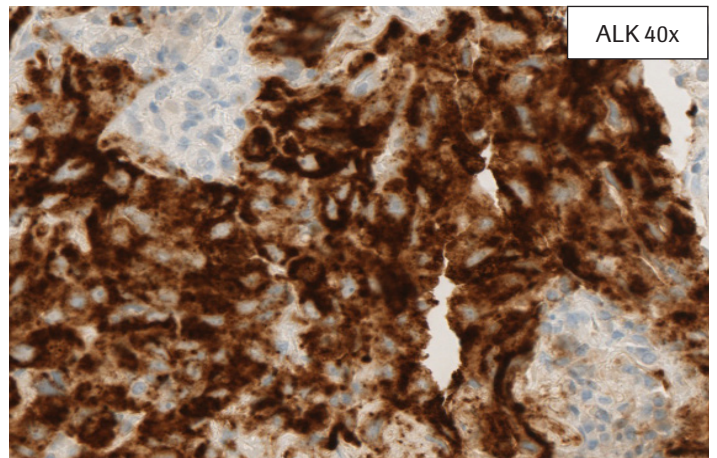
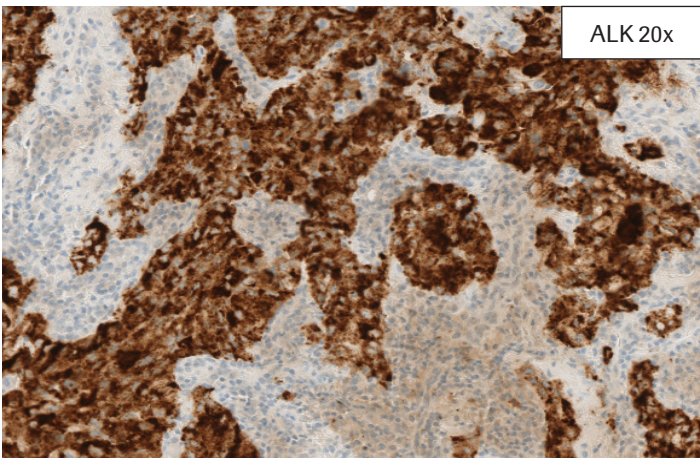
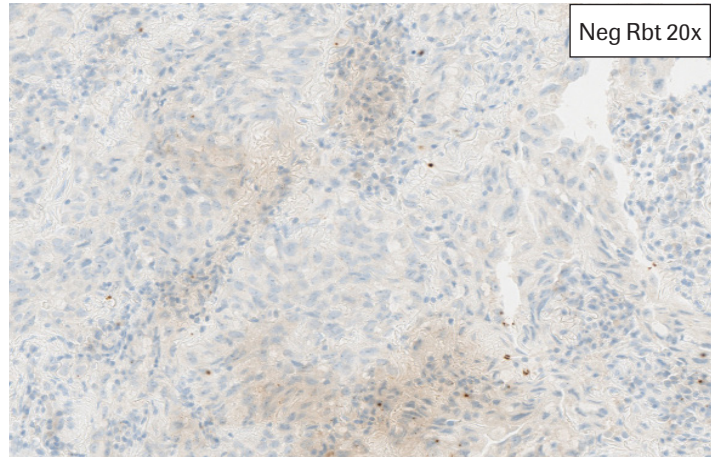
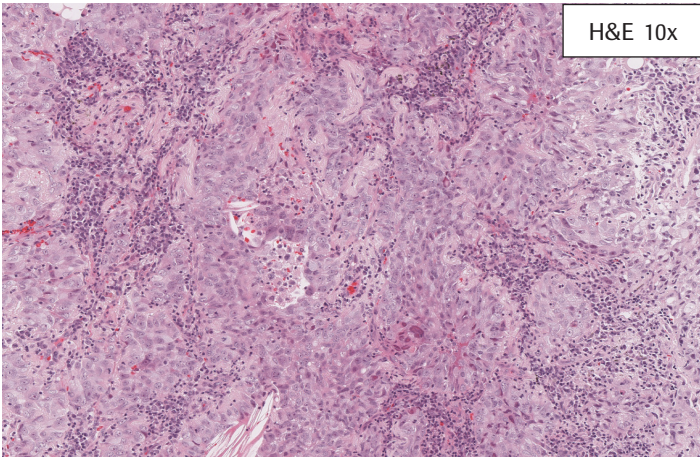
Positive Cases

Positive Cases

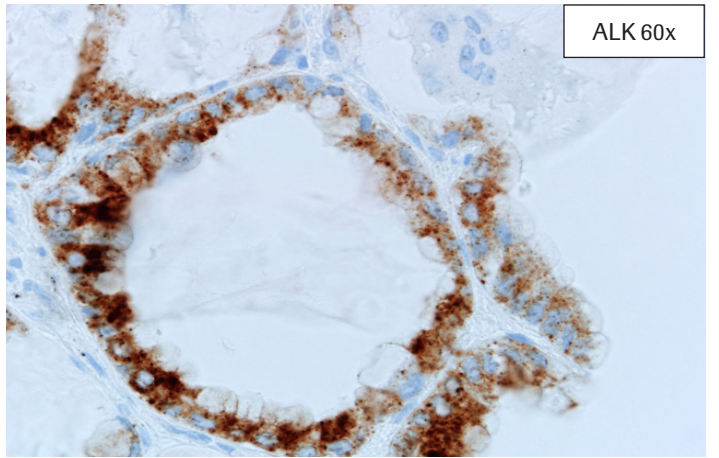
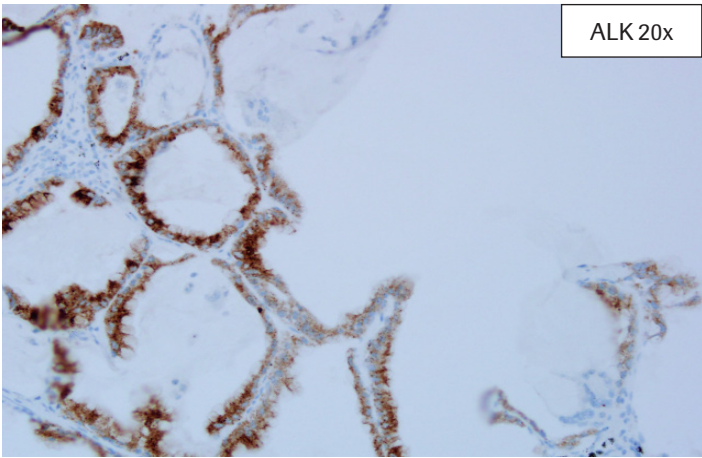
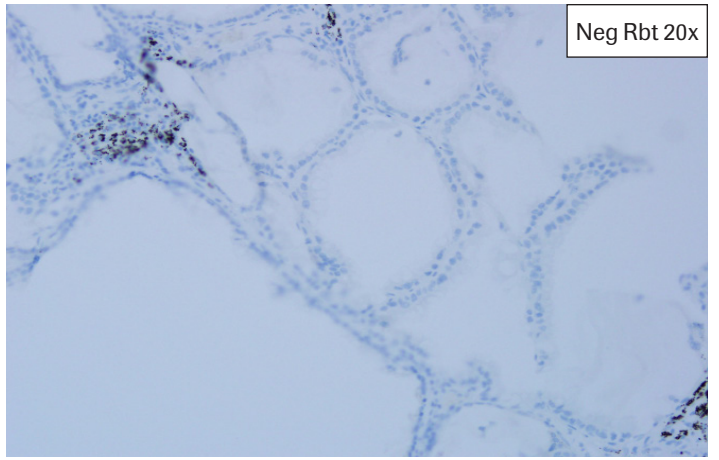
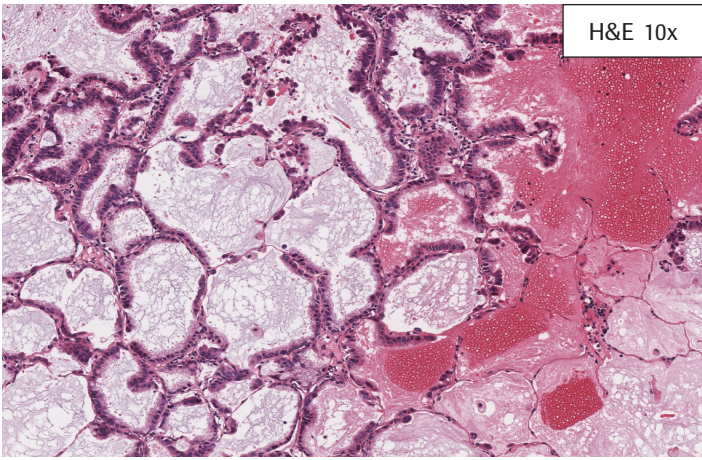
A case is assigned a Positive Clinical Diagnosis for ALK status if strong granular cytoplasmic staining of the tumor cell is observed.



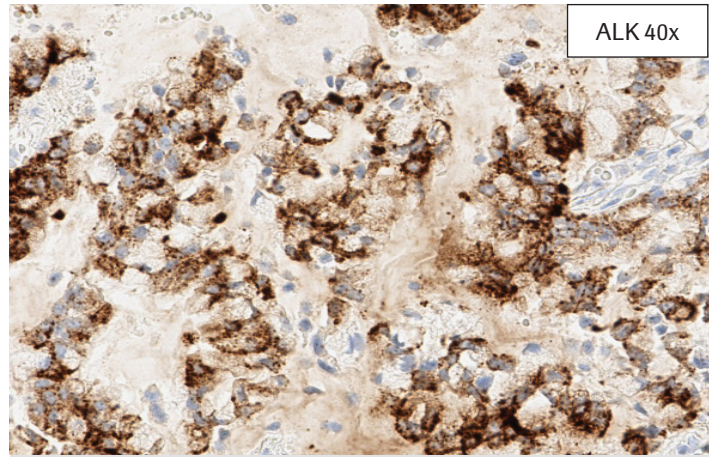
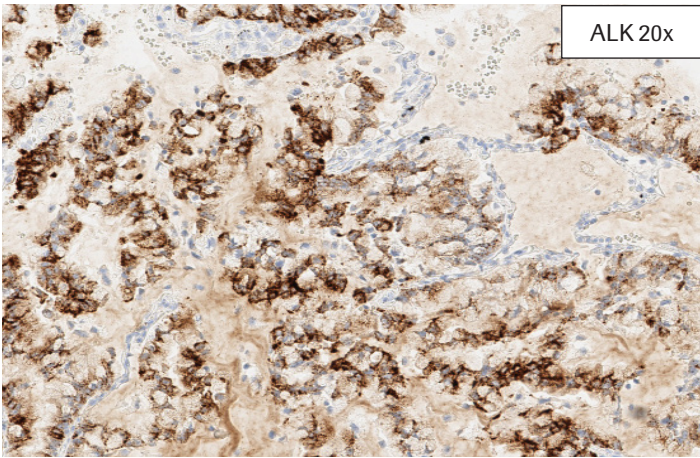
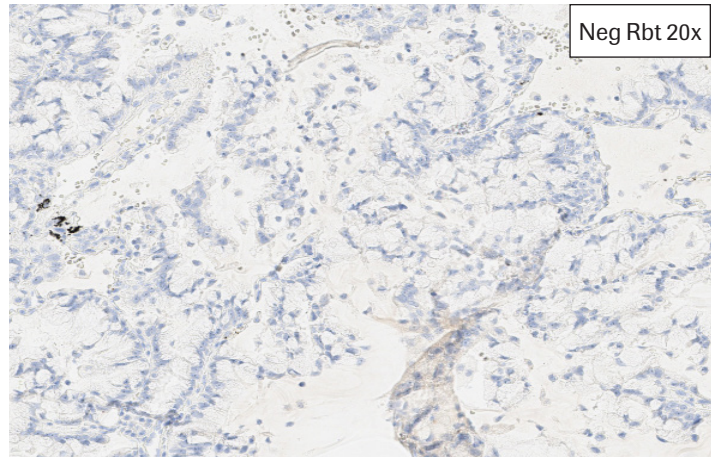
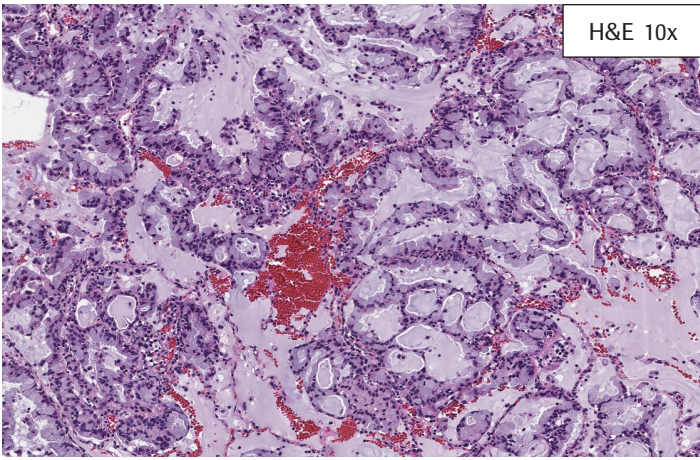
Positive Case 1 exhibits a homogeneous strong granular cytoplasmic staining throughout the tumor. This case is assigned a Positive Clinical Diagnosis for ALK status.



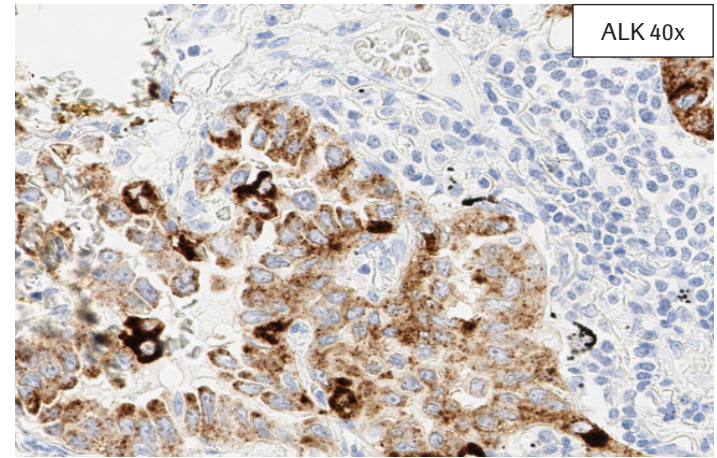
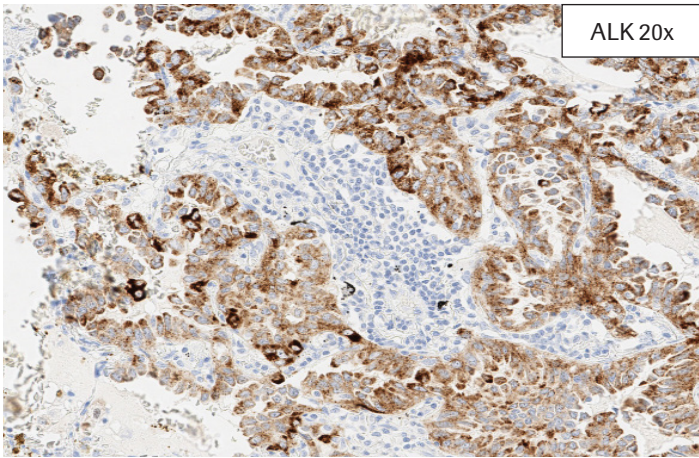
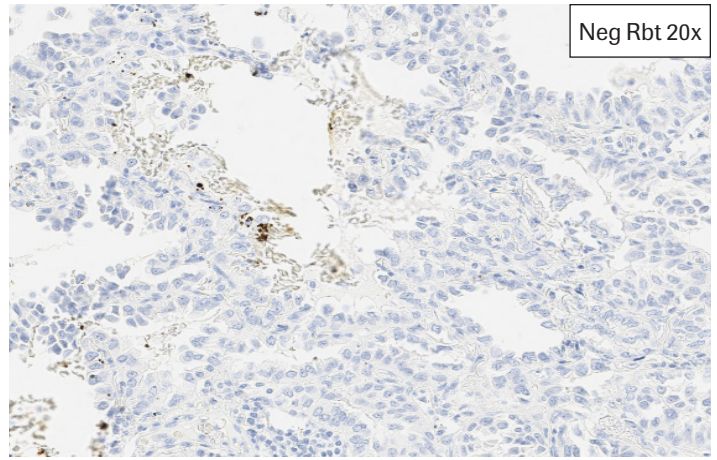
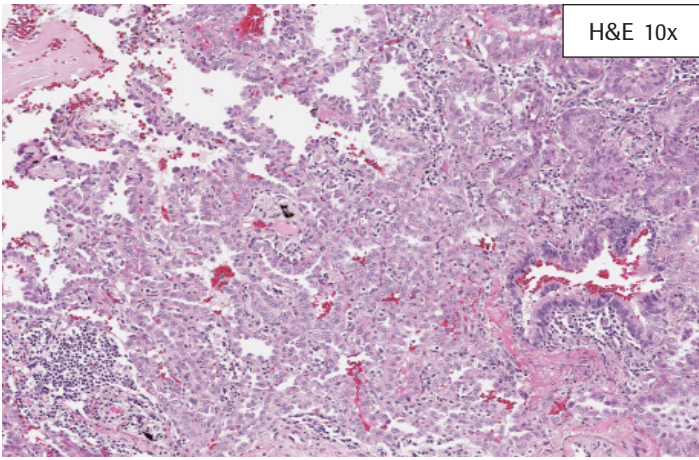
Positive Case 2 exhibits a homogeneous strong granular cytoplasmic staining throughout the tumor. This case is assigned a Positive Clinical Diagnosis for ALK status.



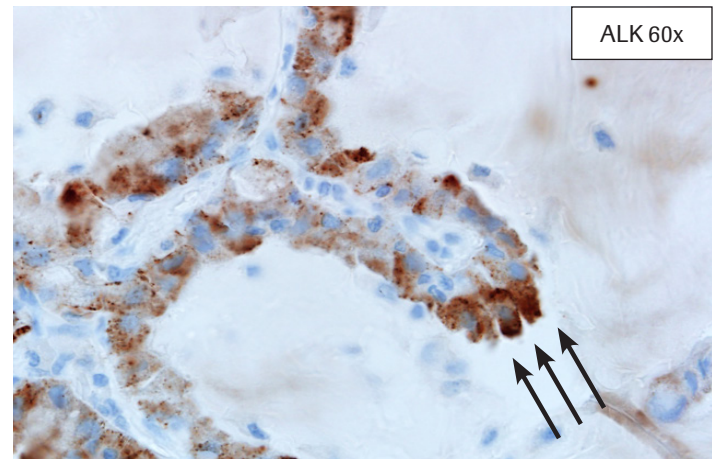
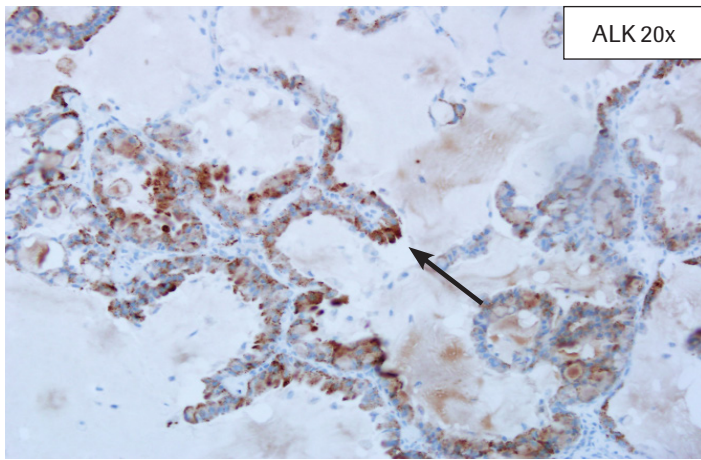
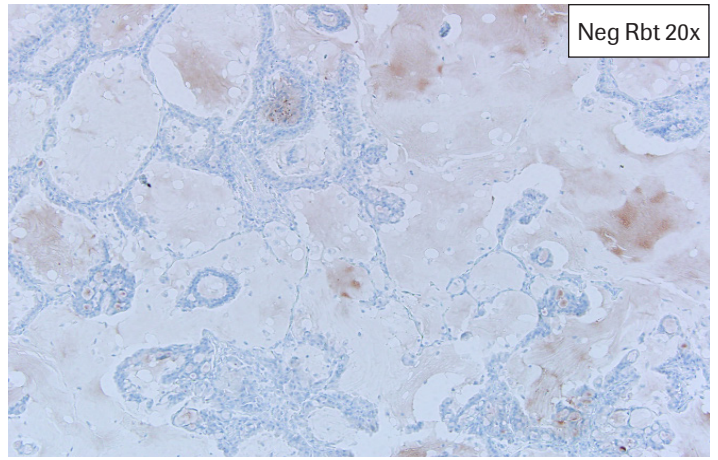
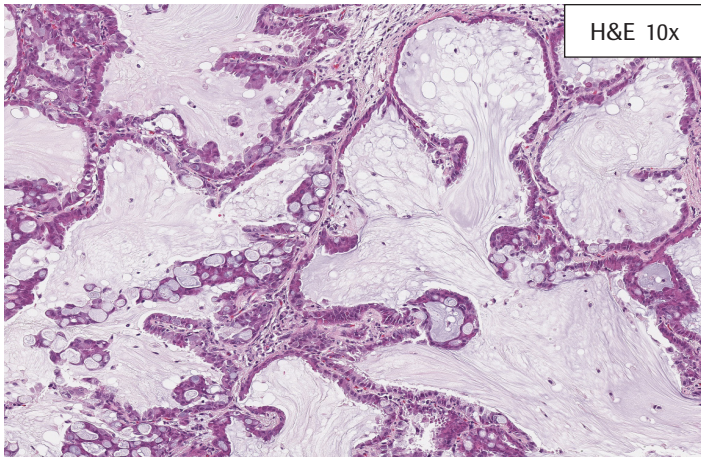
Positive Case 3 exhibits heterogeneous granular cytoplasmic staining throughout sections of the tumor with strong granular cytoplasmic staining in some tumor cells. This case is assigned a Positive Clinical Diagnosis for ALK status.



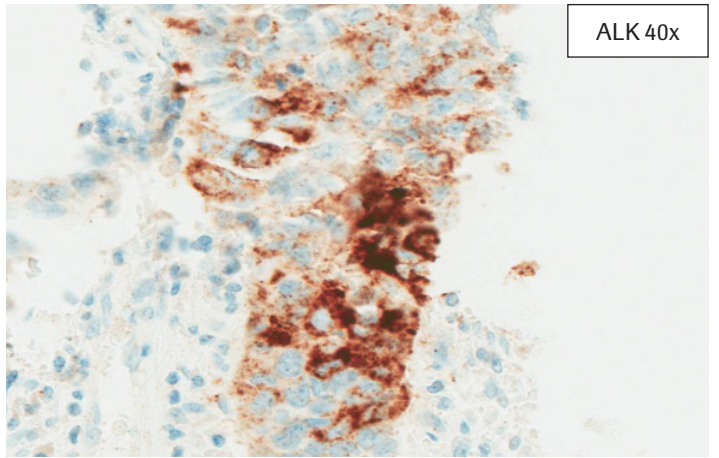
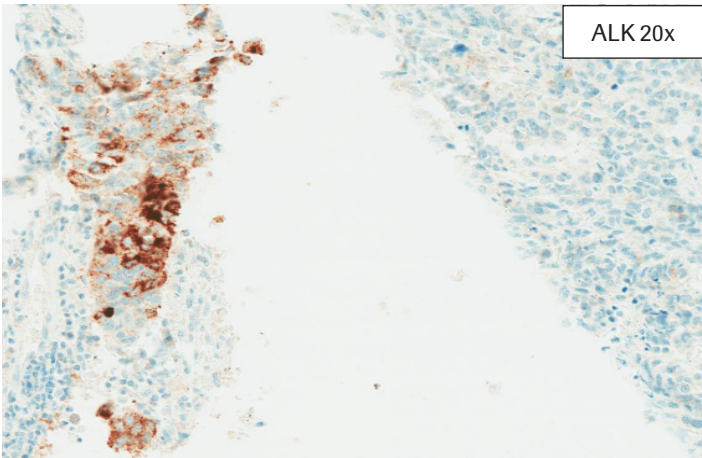
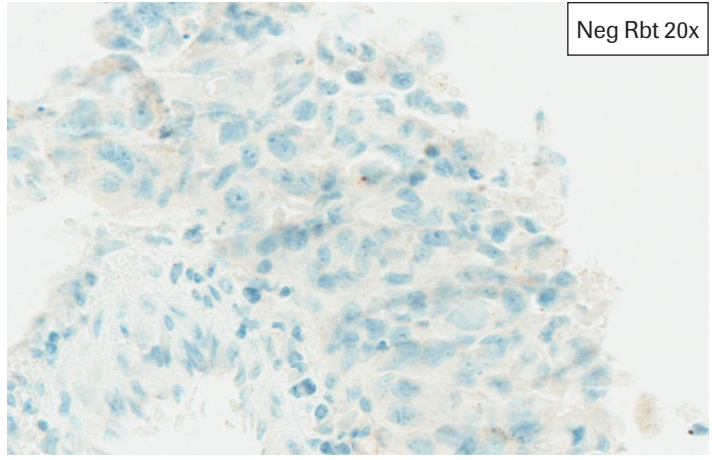
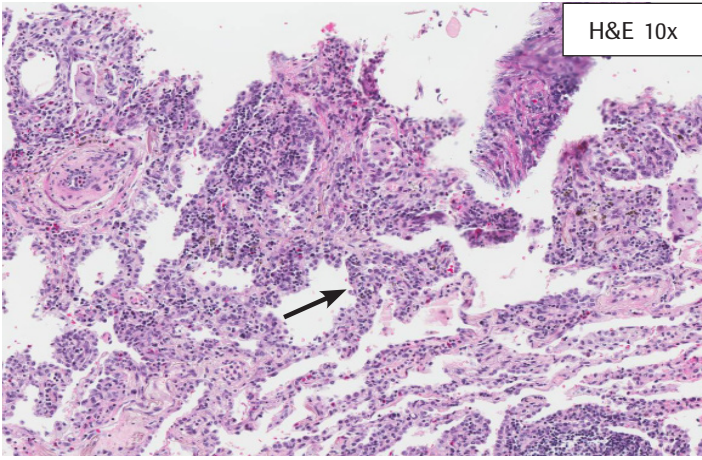
Positive Case 4 exhibits a heterogeneous granular cytoplasmic staining pattern throughout sections of the tumor with strong granular cytoplasmic staining in some tumor cells. This case is assigned a Positive Clinical Diagnosis for ALK status



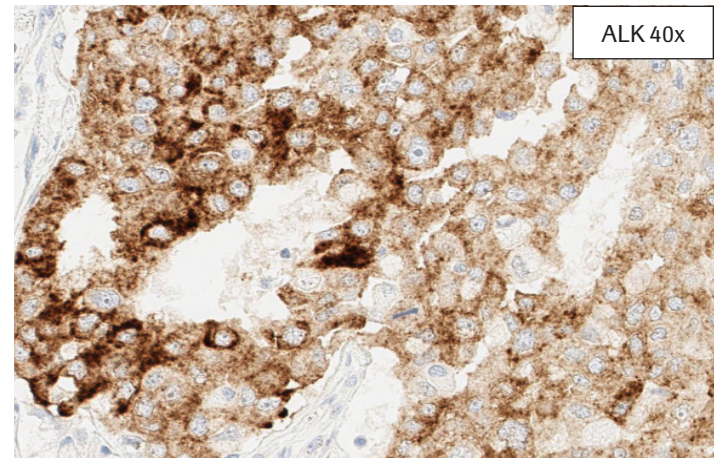
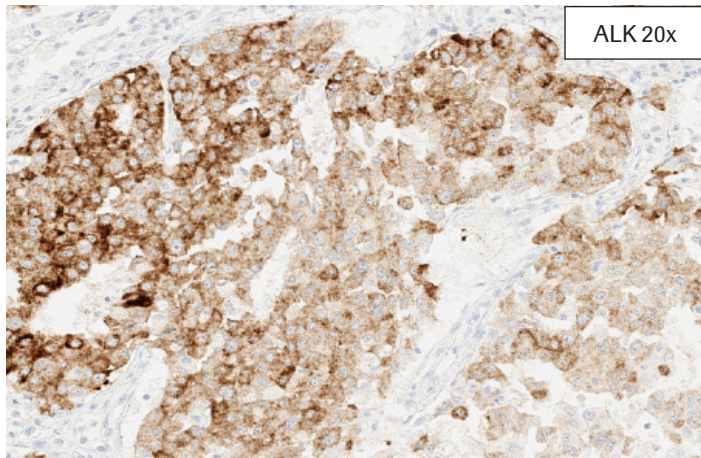
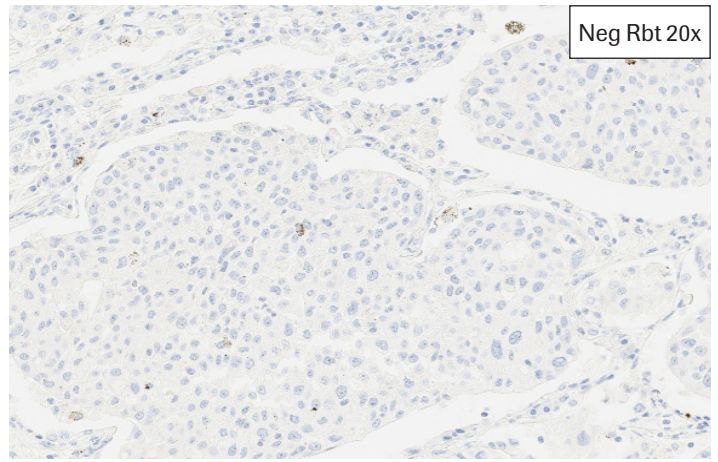
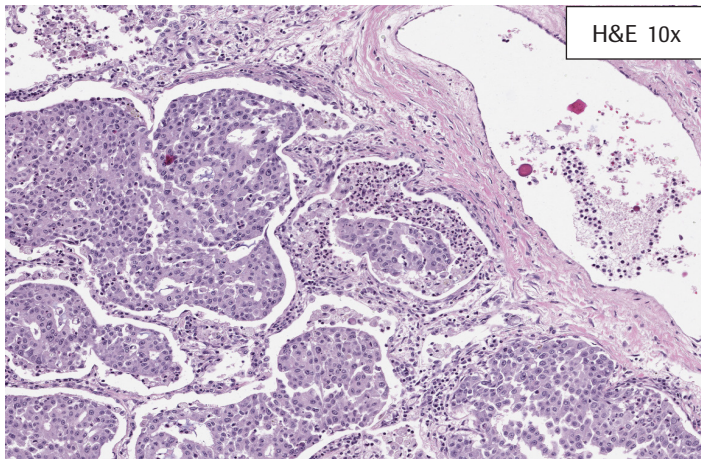
Positive Case 5 exhibits a heterogeneous granular cytoplasmic staining pattern throughout sections of the tumor with strong granular cytoplasmic staining in few tumor cells. This case is assigned a Positive Clinical Diagnosis for ALK status.



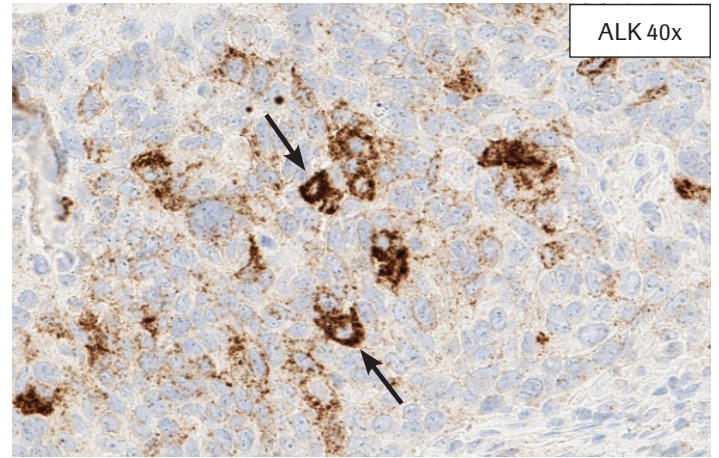
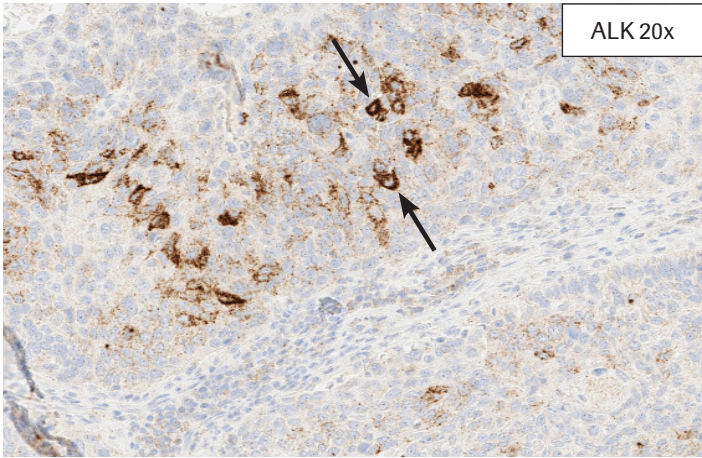
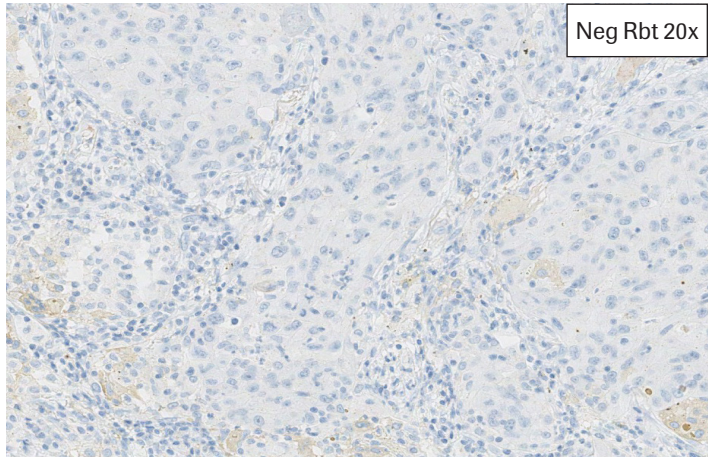
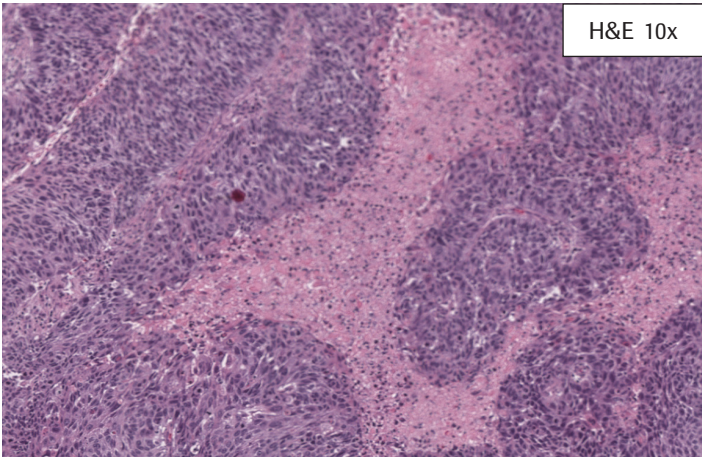
Positive Case 6 exhibits strong granular cytoplasmic staining (see arrows) in few tumor cells. This case is assigned a Positive Clinical Diagnosis for ALK status.



Positive Case 7 exhibits strong granular cytoplasmic staining in few tumor cells. This case is assigned a Positive Clinical Diagnosis for ALK status.



Positive Case 8 exhibits strong granular cytoplasmic staining in few tumor cells (see arrow). This case is assigned a Positive Clinical Diagnosis for ALK status.



Positive Case 9 exhibits strong granular cytoplasmic staining in few tumor cells (see arrows). This case is assigned a Positive Clinical Diagnosis for ALK status.

Challenging Cases

Challenging cases and known staining artifacts

While the vast majority of cases stained with VENTANA ALK (D5F3) CDx Assay are clearly positive or negative in their staining results, a few cases have been observed that present a challenge in interpretation.

- **Non-specific background**

A small percentage of negative cases display a weak, diffuse granular cytoplasmic pattern that is detected above background staining observed on the associated Rabbit Monoclonal Negative Control Ig stained slide. Ventana has estimated these cases represent ~1-2% of all cases stained to date with the VENTANA ALK (D5F3) CDx Assay and are negative by FISH.

- **Granular cytoplasmic staining in normal tissue elements**

Granular cytoplasmic staining in alveolar macrophages and benign glandular epithelial cells may be present on both the ALK and negative reagent control-stained slides. Additionally, neuronal tissue elements may stain positive for ALK. This staining should be excluded in slide interpretation as it is present in normal tissue elements but not in the tumor cells.

- **Non-specific staining of mucin**

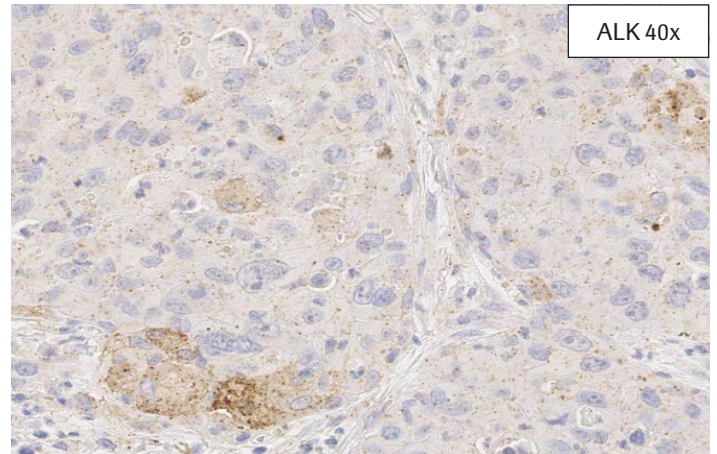
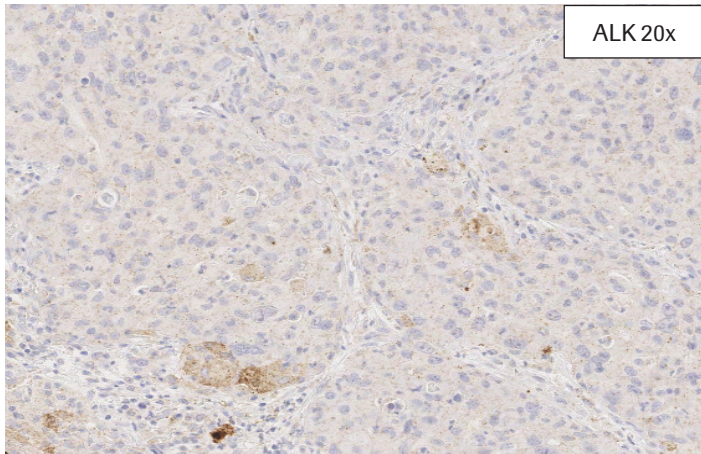
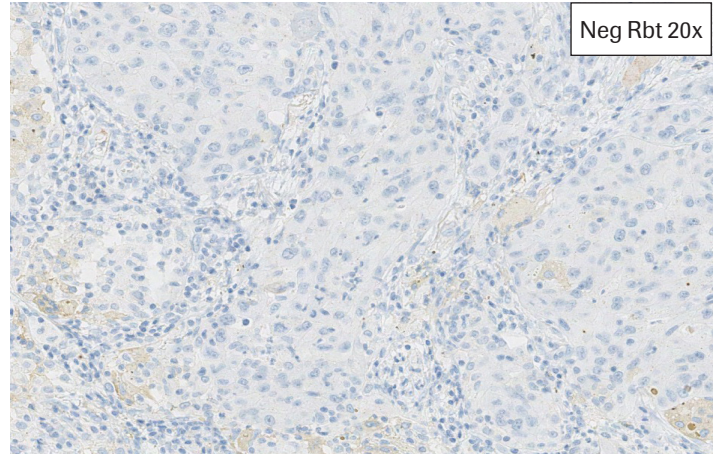
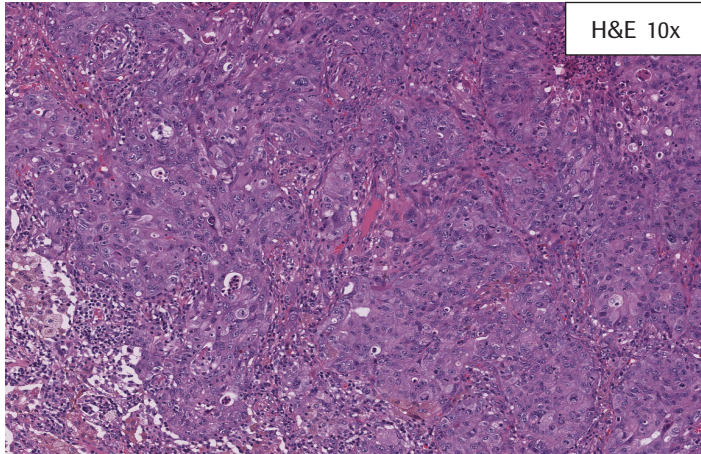
Non-specific staining of mucin should be excluded from slide interpretation providing that the staining does not interfere with interpretation of the slide.

- **Tissue or Staining Artifacts**

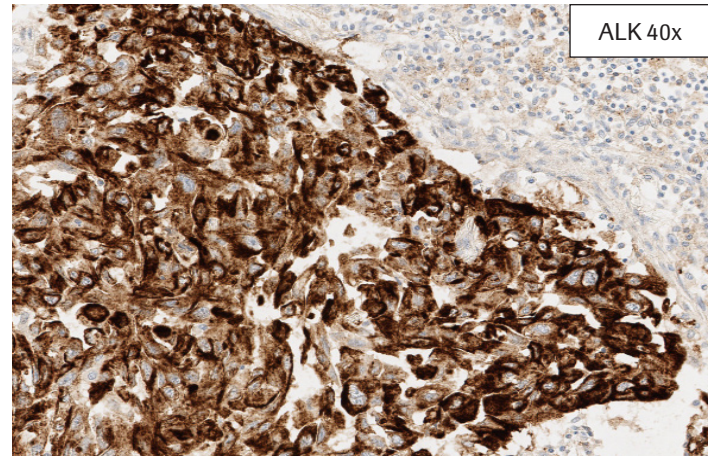
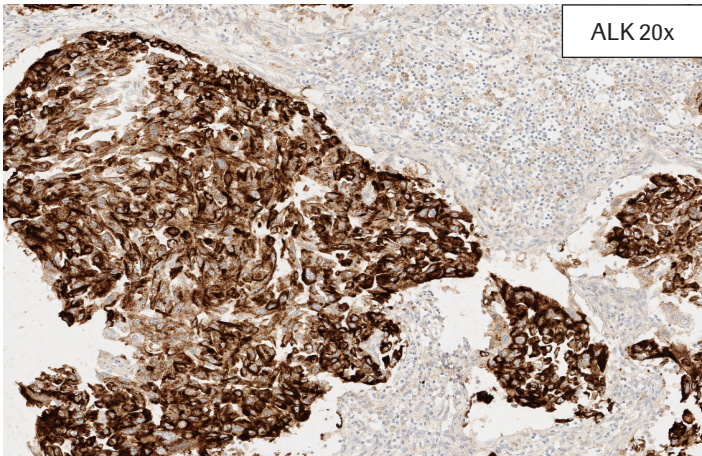
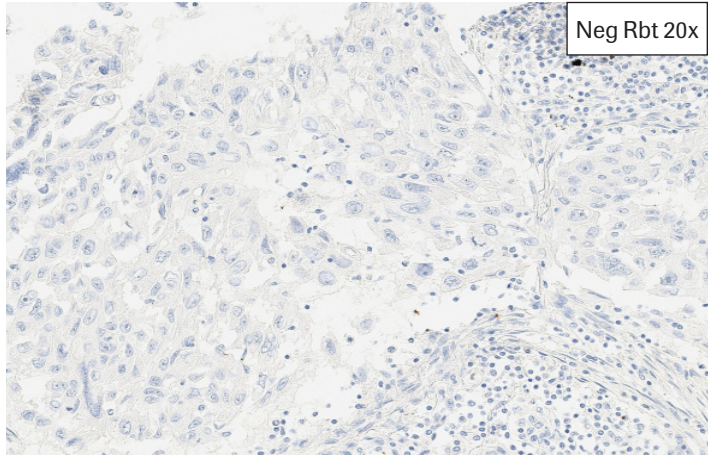
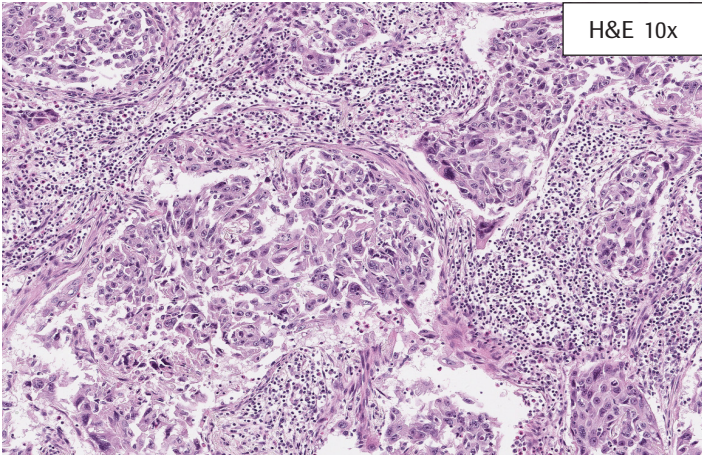
Histologic artifacts originating from the sample processing and microtomy processes can also complicate the determination of an ALK Clinical Diagnosis. These artifacts may include, but are not limited to: fixation gradients and edge effects, DAB trapping, lack of staining in some regions of the tissue, tearing or folding of the tissue, and loss of the tissue section. In some instances, repeat staining of new sections or acquisition of a new specimen may be required.

Some examples of challenging cases are shown on the following pages.

Challenging cases: Non-specific background staining

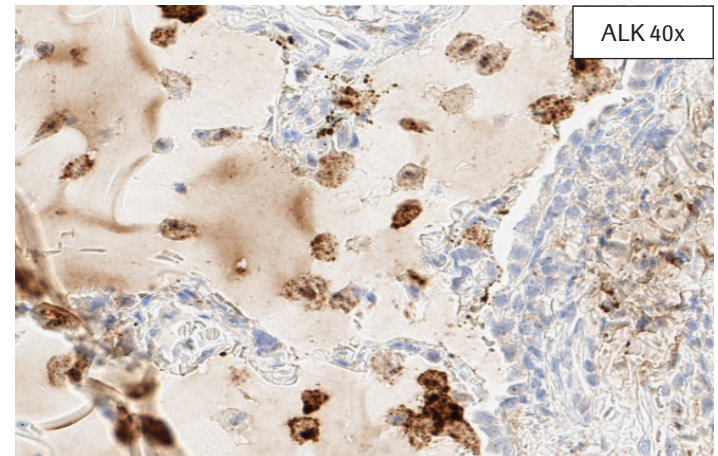
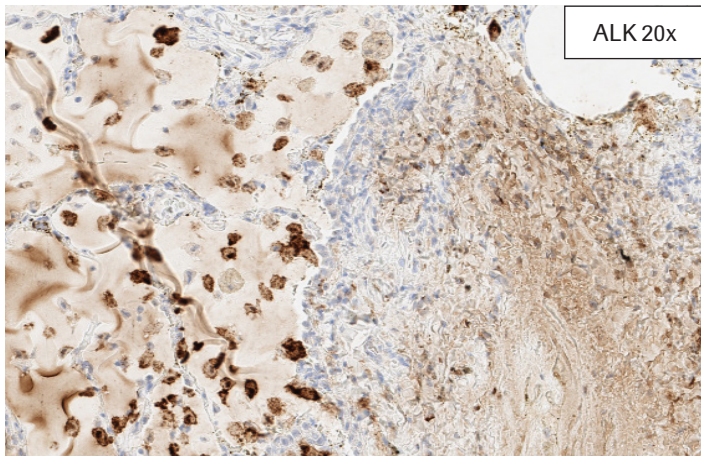
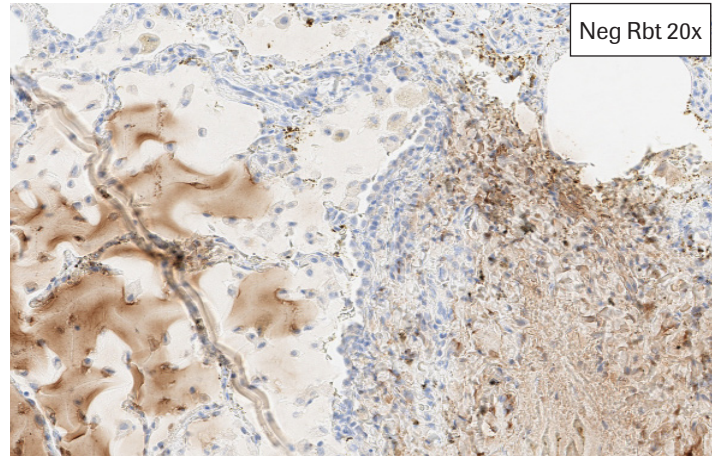
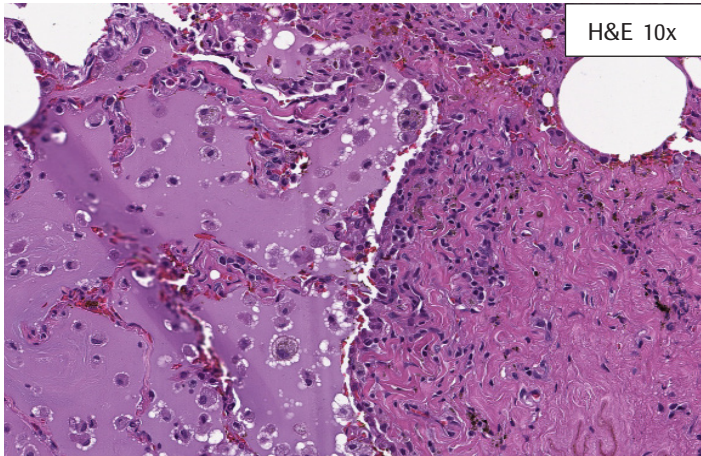


Challenging case 1: Negative This case displays a non-specific diffuse granular cytoplasmic pattern throughout the tissue that is detected above background staining observed on the associated Rabbit Monoclonal Negative Control Ig- stained slide. This case is assigned a Negative Clinical Diagnosis for ALK status.



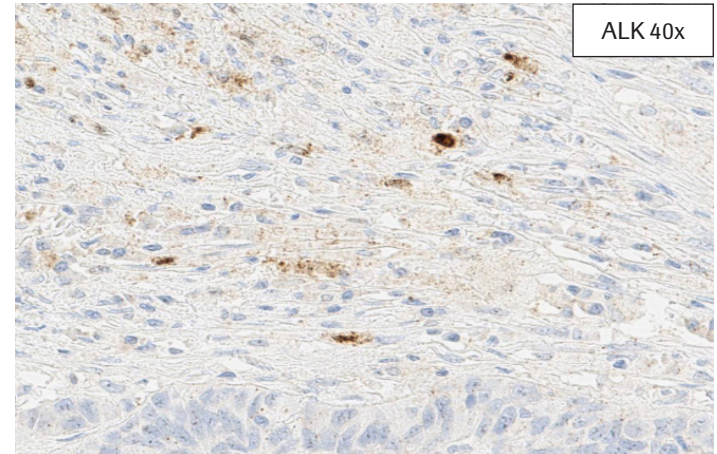
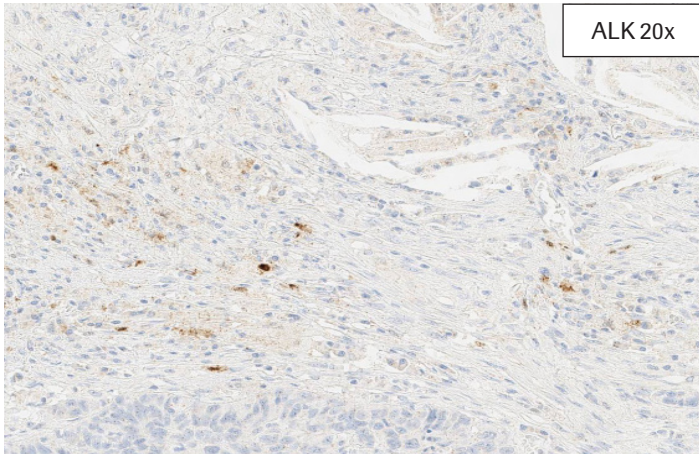
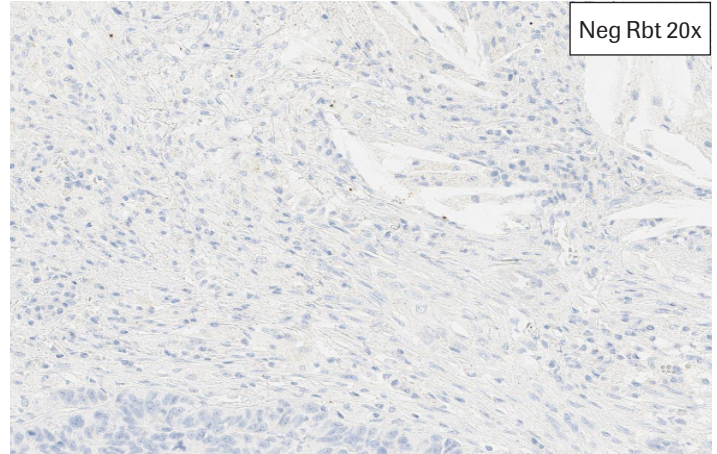
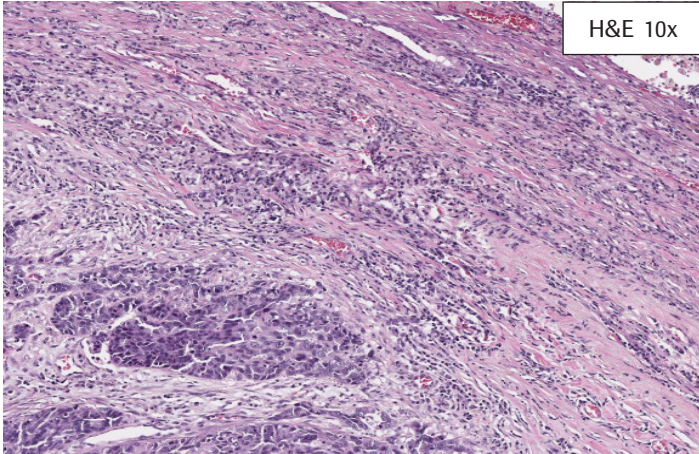
Challenging case 2: Positive This case displays a non-specific diffuse granular cytoplasmic staining in the stroma that is detected above background staining observed on the associated Rabbit Monoclonal Negative Control Ig- stained slide. This case is assigned a Positive Clinical Diagnosis for ALK status, and background is considered acceptable as it does not interfere with interpretation of the specific stain.

Challenging cases: Granular cytoplasmic staining in alveolar macrophages



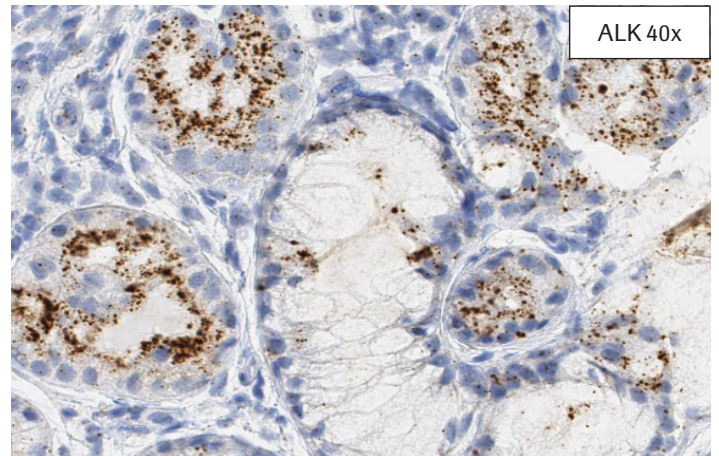
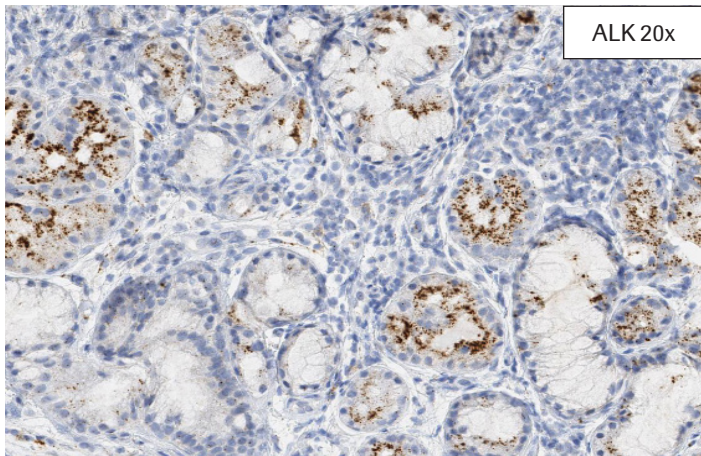
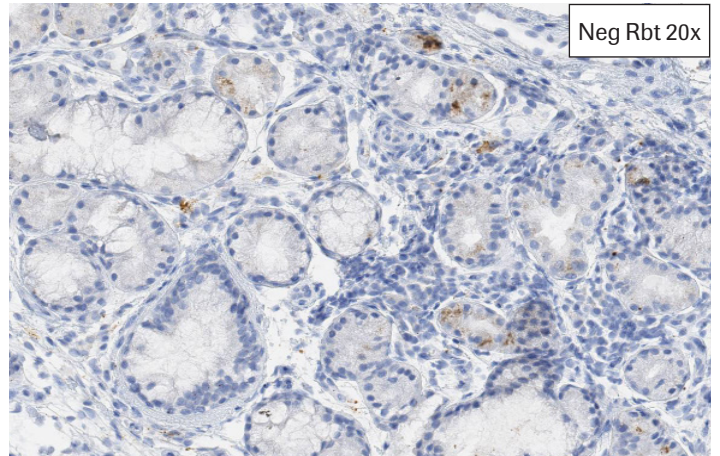
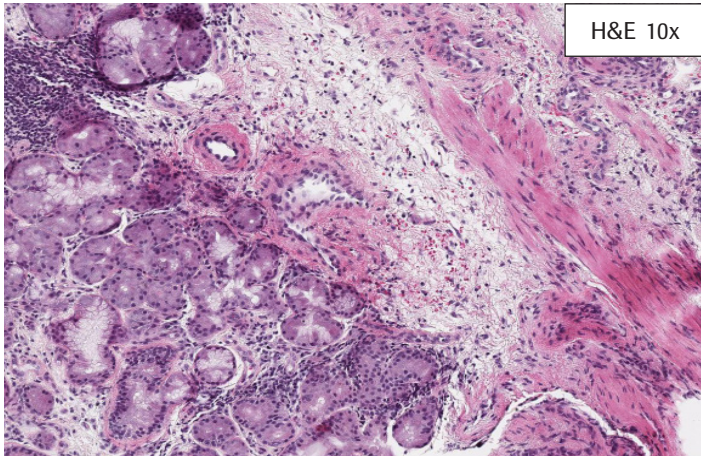
Challenging case 3: Negative Strong granular cytoplasmic staining may be present in alveolar macrophages and should not be interpreted as an ALK-positive diagnosis. When evaluating a NSCLC for ALK staining it is imperative to closely examine the cell type staining to ensure that it is tumor. These staining artifacts should be excluded in slide interpretation as it is present in normal tissue elements. This case is assigned a Negative Clinical Diagnosis for ALK status.

Challenging cases: Granular cytoplasmic staining in scattered lymphoreticular cells within lymphocytic infiltrate



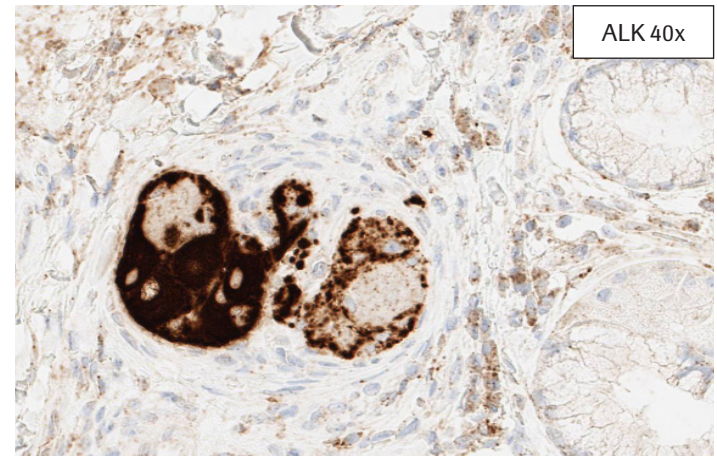
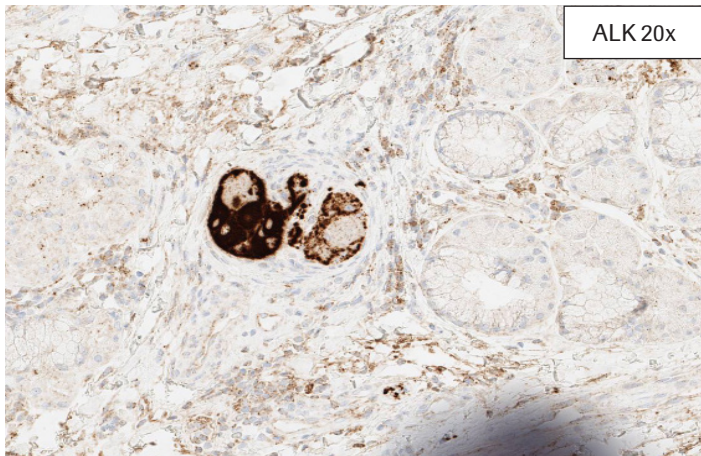
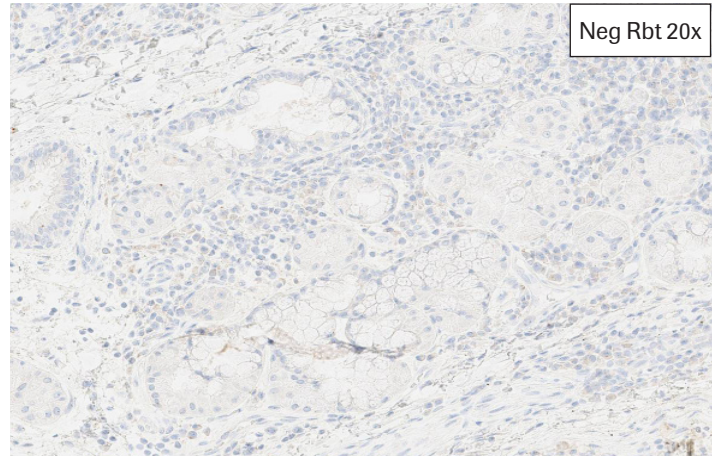
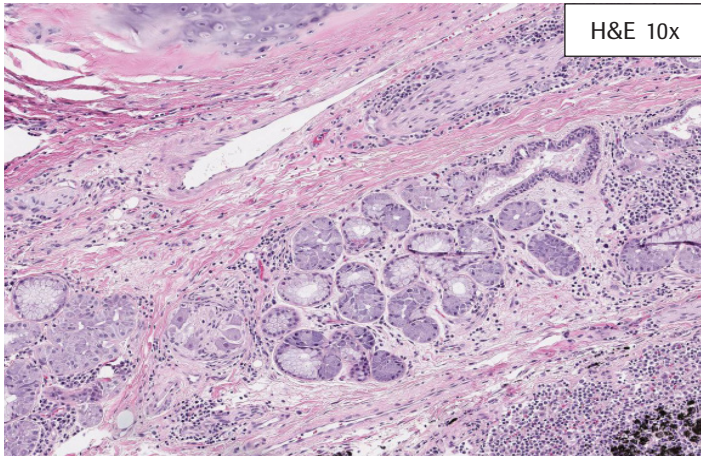
Challenging case 4: Negative Strong granular cytoplasmic staining may be present in lymphoreticular cells within lymphocytic infiltrate and should not be interpreted as an ALK-positive diagnosis. When evaluating a NSCLC for ALK staining it is imperative to closely examine the cell type staining to ensure that it is tumor. This staining should be excluded in slide interpretation as it is present in normal tissue elements. This case is assigned a Negative Clinical Diagnosis for ALK status.

Challenging cases: Granular cytoplasmic staining in benign glandular epithelium



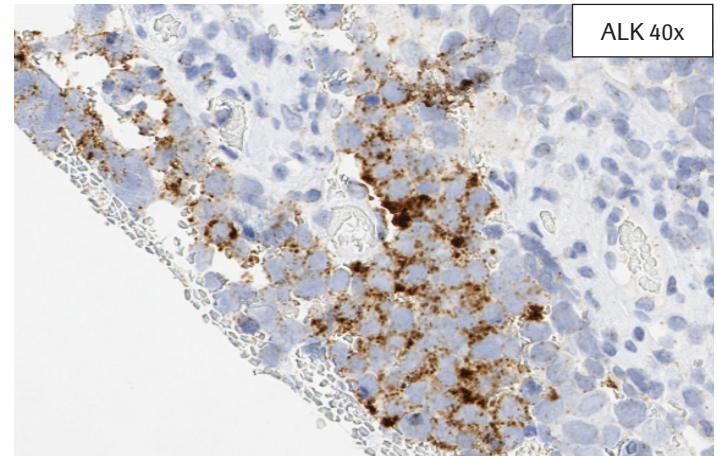
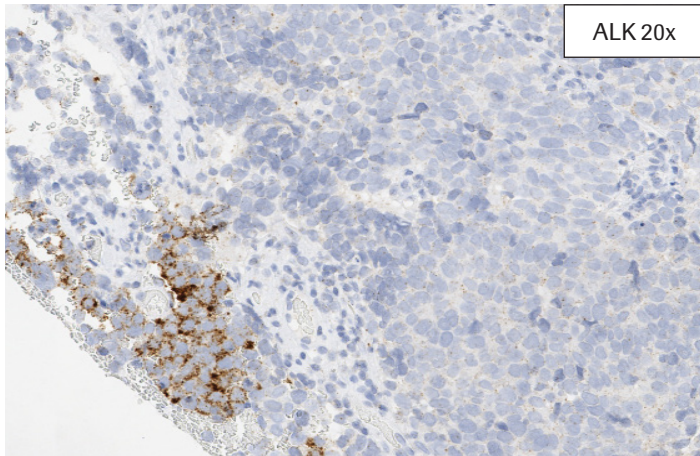
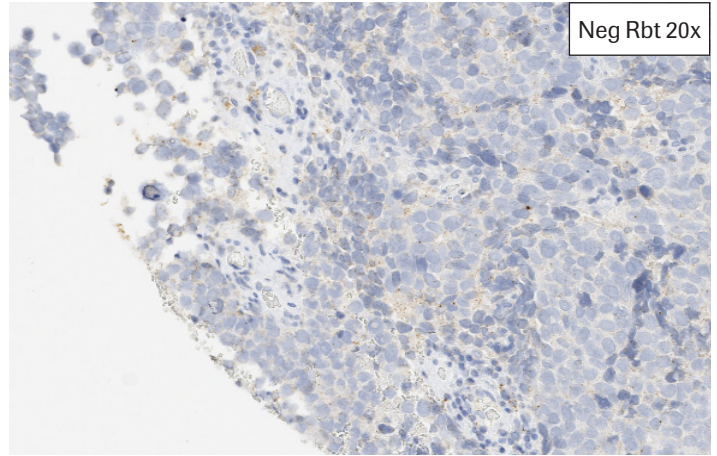
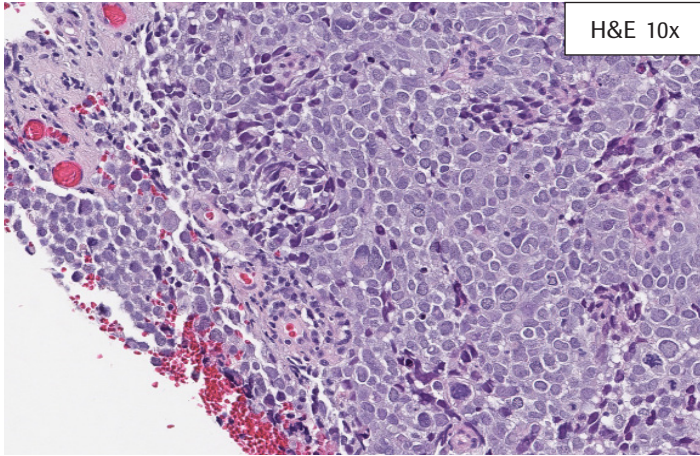
Challenging case 5: Negative Granular cytoplasmic staining in benign glandular epithelium may be present on the ALK -stained slides. These staining artifacts should be excluded in slide interpretation as it is present in normal tissue elements but not in the tumor cells. This case is assigned a Negative Clinical Diagnosis for ALK status.

Challenging cases: Granular cytoplasmic staining in ganglion cells



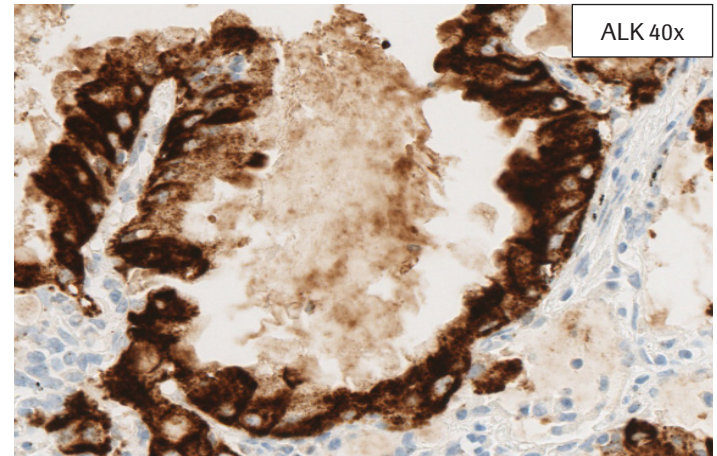
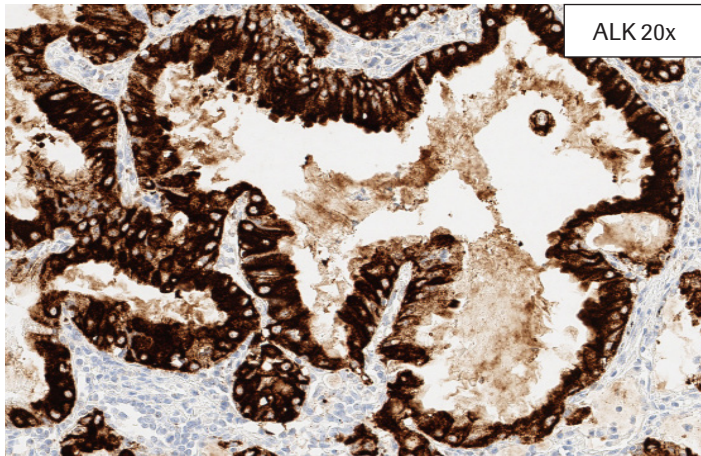
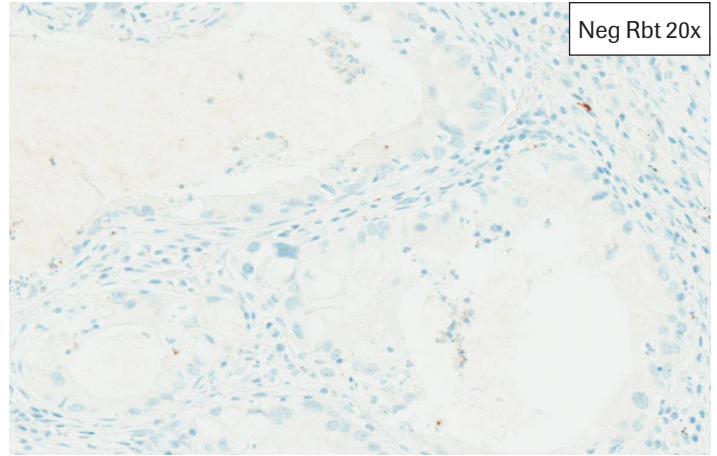
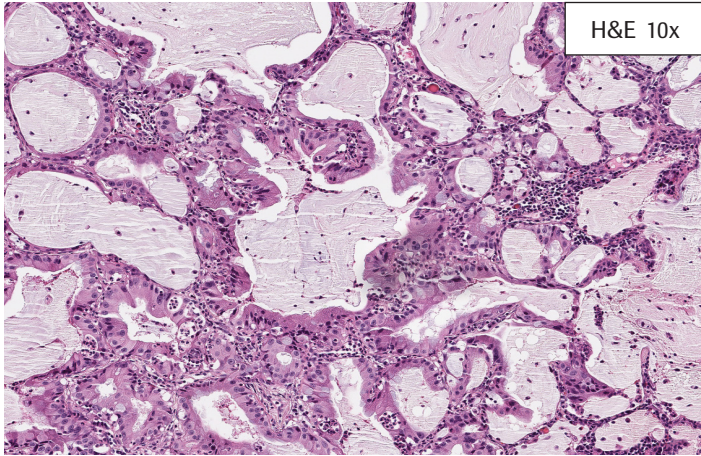
Challenging case 6: Negative Granular cytoplasmic staining in ganglion cells may be present on the VENTANA ALK (D5F3) CDx Assay-stained slides. This staining should be excluded in slide interpretation as it is present in normal tissue elements but not in the tumor cells. This case is assigned a Negative Clinical Diagnosis for ALK status.

Challenging cases: Strong granular membrane ALK-staining



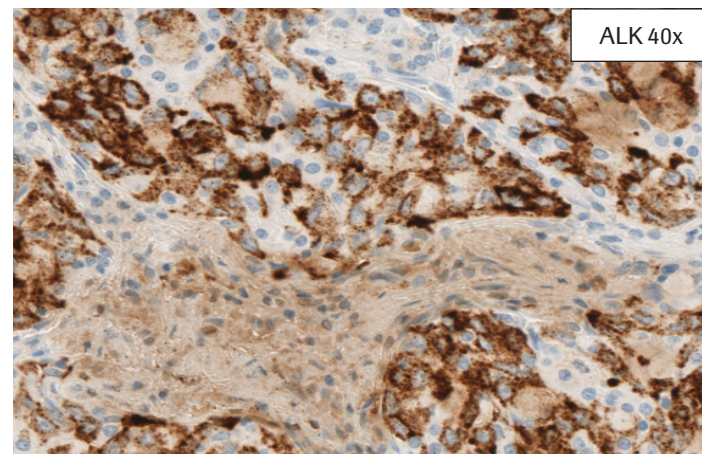
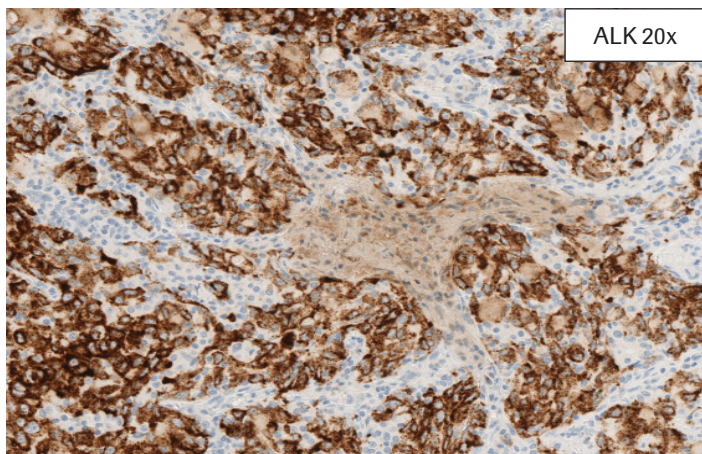
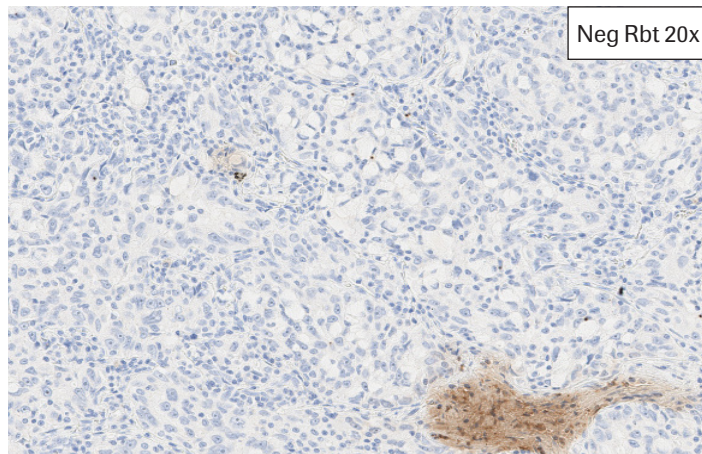
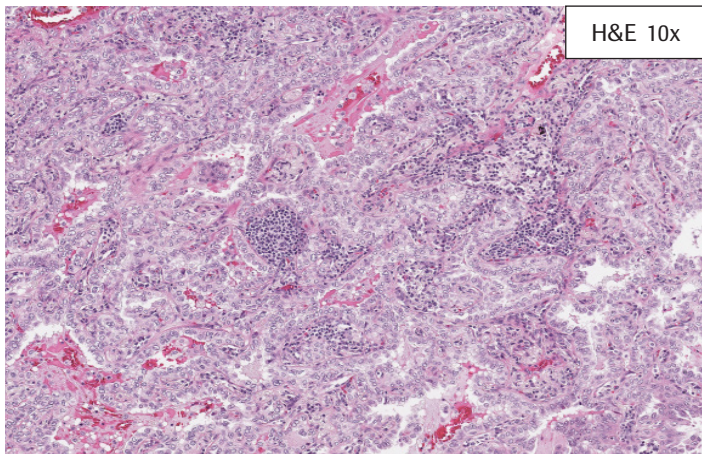
Challenging case 7: Negative Membrane or non-cytoplasmic staining should not be interpreted as an ALK-positive diagnosis for this case. ALK-positive specific staining must be strong granular cytoplasmic staining within viable tumor cells. This case is assigned a Negative Clinical Diagnosis for ALK status.

Challenging cases: Mucin staining



Challenging case 8: Positive Staining of mucin should be excluded from slide interpretation providing that the staining does not interfere with interpretation of the case. This case is assigned a Positive Clinical Diagnosis for ALK status.

Challenging cases: DAB trapping



Challenging case 9: Positive Occasionally, cases may have DAB trapping within the tissue. This artifact should be excluded from slide interpretation providing that the trapping does not interfere with interpretation of the case. Otherwise the specimen should be restained. This case is assigned a Positive Clinical Diagnosis for ALK status.

Reproducibility of the VENTANA ALK (D5F3) CDx Assay

The advantage of the VENTANA ALK (D5F3) CDx Assay is that the use of the OptiView DAB IHC Detection Kit and OptiView Amplification Kit enables the vast majority of NSCLC cases to easily be interpreted as a “Positive” or “Negative” result. The enhanced sensitivity of the assay means that the reader does not need to provide a semi-quantitative assessment of percent tumor cell staining or staining intensities, as is the case for other biomarkers assessed by IHC assays. However, Ventana recognizes that the OptiView Amplification Kit is new technology for many pathologists. One factor that is apparent in more sensitive detection systems is that there can be more slide-to-slide variability in total staining intensity, compared with DAB only.

Pre-Analytical Conditions and Their Impact on VENTANA ALK (D5F3) CDx Assay Staining

Pre-Analytical Conditions and Their Impact on VENTANA ALK (D5F3) CDx Assay Staining

Fixative Examples (Xenografts)

Ventana has conducted studies using the NCI-H2228 cell line (positive for ALK) generated as xenograft tumors in SCID mice as a model system for determining the impact of pre-analytical factors on the assay. The tumors were harvested and fixed with different fixatives across a range of times and stained with the VENTANA ALK (D5F3) CDx Assay.

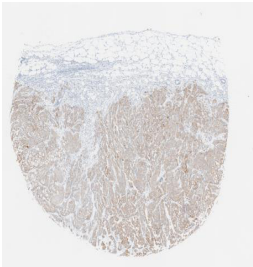
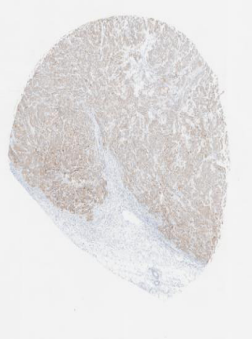
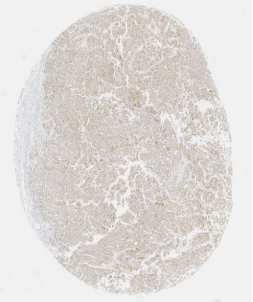
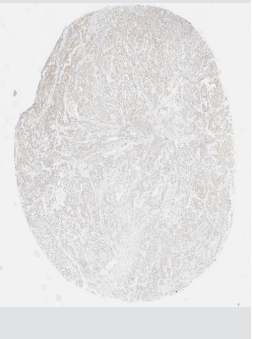
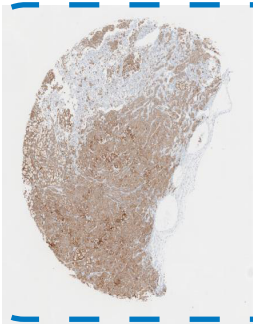
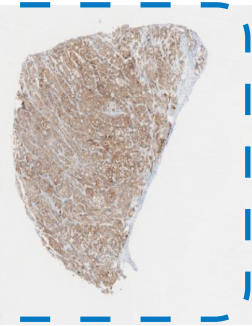
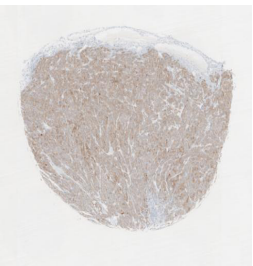
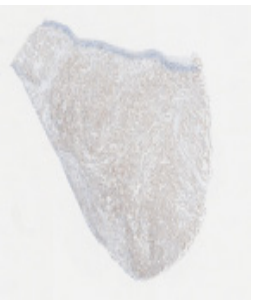
Consistent with ASCO/CAP guidelines for HER2 testing, tissues must be fixed using 10% neutral buffered formalin (NBF) for a period of at least 6 hours, for optimal VENTANA ALK (D5F3) CDx Assay staining results.¹²⁻¹⁵ Zinc formalin also yielded acceptable staining results at >6 hour time-points, and can be used with the ALK assay. However, fixation times below 6 hours (under-fixation) in NBF and in Zinc formalin resulted in a significant decrease in staining intensity for ALK.

Fixatives other than NBF and Zinc formalin, including AFA, B5, and Prefer, also were tested and should not be used with the VENTANA ALK (D5F3) CDx Assay as the staining results were severely compromised. Intensity of VENTANA ALK (D5F3) CDx Assay was dramatically decreased under all time-points tested with AFA, B5, and Prefer fixatives. In addition, fixing in 95% alcohol for as little as one hour resulted in a significant negative impact to ALK staining intensity and should not be performed with this assay.

Ventana also investigated the impact that delay to fixation has on the VENTANA ALK (D5F3) CDx Assay staining results. Xenograft samples were excised and left un-fixed for times ranging from 30 minutes to 24 hours, then fixed for 12 hours in 10% NBF. The staining results indicated that ALK intensity was compromised if the time to fixation in NBF was delayed >6 hours.

Finally, it is important to emphasize that the ALK protein appears to be more sensitive to pre-analytical factors when compared with other lung markers detected by IHC (such as TTF1 and EGFR) using the xenograft models. Representative data are shown below. Ventana emphasizes that fixation conditions for human lung specimens be carefully monitored and controlled to ensure optimal staining results with VENTANA ALK (D5F3) CDx Assay.

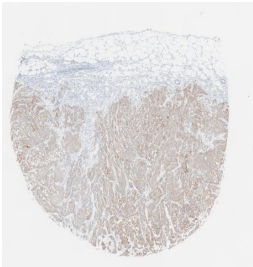
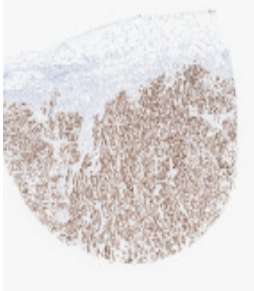
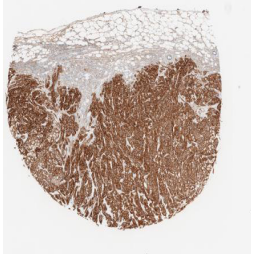
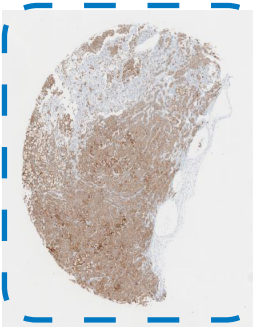
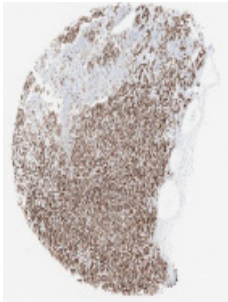
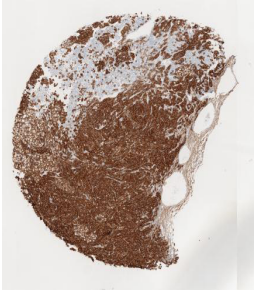
Examples of the Impact of Fixation Conditions with VENTANA ALK (D5F3) CDx Assay

Fixation Time (Hours)	Fixative			
	10% NBF	Zinc Formalin	AFA	95% Ethanol
1				
12				

Ventana recommends fixation in 10% NBF for 6–48 hours. ALK staining results within the dotted line are acceptable. Fixation for less than 6 hours is not recommended. The use of Prefer, Bouin's (not pictured), and alcohol fixatives, such as AFA and 95% Ethanol, is not recommended due to weaker staining.

It is important to emphasize that the ALK protein (as detected by the VENTANA ALK (D5F3) CDx Assay and the anti-ALK 5A4 clone) appears to be more sensitive to pre-analytical factors when compared with other lung markers detected by IHC (TTF1 and EGFR) using the xenograft models. Representative images are shown below. Ventana emphasizes that fixation conditions for human lung specimens be carefully monitored and controlled to ensure optimal staining results with the VENTANA ALK (D5F3) CDx Assay.

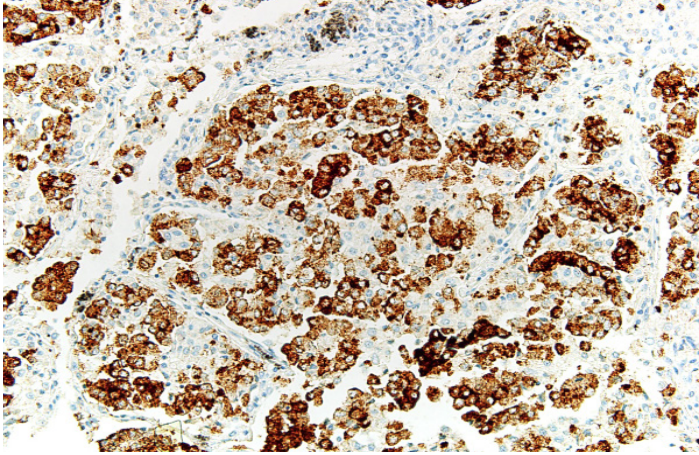
Comparison of IHC lung markers fixed with 10% NBF

10% NBF Fixation Time (Hours)	IHC Lung Marker		
	ALK	TTF-1	EGFR
1			
12			

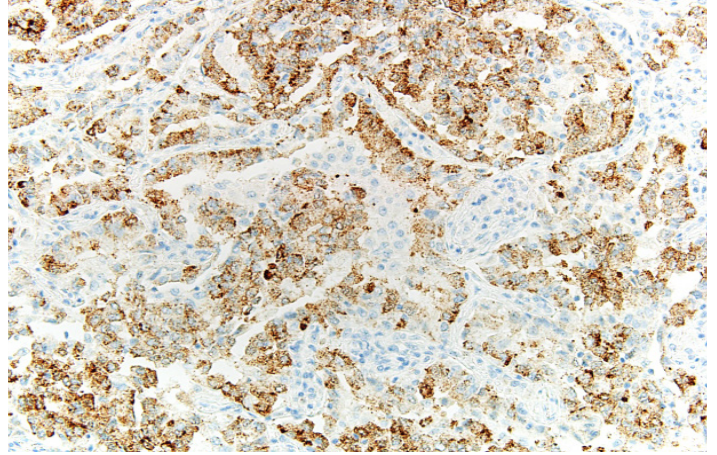
Note that when comparing fixation times between 1 and 12 hours, TTF-1 and EGFR do not exhibit the same loss of staining intensity as ALK.. ALK staining result within the dotted line is clinically positive; whereas, 1 hour fixation (pictured above) represents clinically negative staining. Therefore, Ventana recommends 10% NBF fixation times not less than 6 hours.

Cut Slide Stability

Ventana has determined that VENTANA -ALK (D5F3) CDx Assay should not be performed on cut slides that have been stored longer than 3 months. The intensity of the staining decreased when slides were stored at room temperature (although none of the ALK positive cases tested at that time point changed its status from ALK positive to ALK negative). Examples are shown below. Ventana has not tested the impact of cut slide stability combined with different fixatives, and 3 months may not be the optimal stability for fixatives other than NBF.



Case 1 freshly sectioned and stained.



Case 1 slides stored ambient (room temperature) for 4 months.

Although both slides are positive for ALK, note diminished staining on the slide stored ambient (room temperature) for 4 months (right panel) compared to the freshly sectioned stained slide (left panel).

References

References

1. Kutok JL, Aster JC. Molecular biology of anaplastic lymphoma kinase-positive anaplastic large-cell lymphoma. *J Clin Oncol*. 2002;20(17):3691-3702.
2. Iwahara T, et al. Molecular characterization of ALK, a receptor tyrosine kinase expressed specifically in the nervous system. *Oncogene*. 1997;14(4):439-449.
3. Soda M, et al. Identification of the transforming EML4-ALK fusion gene in non-small-cell lung cancer. *Nature*. 2007;448(7153):561-66.
4. Inamura K, et al. EML4-ALK fusion is linked to histological characteristics in a subset of lung cancers. *J Thorac Oncol*. 2008;3(1):13-17.
5. Choi YL, et al. Identification of novel isoforms of the EML4-ALK transforming gene in non-small cell lung cancer. *Cancer Res*. 2008;68(13):4971-76.
6. Koivunen JP, et al. EML4-ALK fusion gene and efficacy of an ALK kinase inhibitor in lung cancer. *Clin Cancer Res*. 2008;14(13):4275-83.
7. Shinmura K, et al. EML4-ALK fusion transcripts, but no NPM-, TPM3-, CLTC-, ATIC-, or TFG-ALK fusion transcripts, in non-small cell lung carcinomas. *Lung Cancer*. 2008;61(2):163-169.
8. Takeuchi K, et al. Multiplex reverse transcription-PCR screening for EML4-ALK fusion transcripts. *Clin Cancer Res*. 2008;14(20):6618-24.
9. Shaw AT, et al. Clinical features and outcome of patients with non-small-cell lung cancer who harbor EML4-ALK. *J Clin Oncol*. 2009;27(26):4247-4253.
10. Yi ES, et al. Correlation of IHC and FISH for ALK gene rearrangement in non-small cell lung carcinoma: IHC score algorithm for FISH. *J Thorac Oncol*. 2011;6(3):459-65.
11. McLeer-Florin A, et al. Dual IHC and FISH testing for ALK gene rearrangement in lung adenocarcinomas in a routine practice: a French study. *J of Thorac Oncol*. 2012;7(2):348-54.
12. Sheehan DC, Hrapchak BB. *Theory and practice of Histotechnology*, 2nd edition. St. Louis: C.V. Mosby Company; 1980.
13. Carson F, Hladik C. *Histotechnology: A Self Instructional Text*, 3rd edition. Hong Kong: American Society for Clinical Pathology Press; 2009.
14. College of American Pathologists Laboratory Accreditation Program, *Anatomic Pathology Checklist*, 2011.
15. CLSI. *Quality Assurance for Design Control and Implementation of Immunohistochemistry Assays: Approved Guideline-Second Edition*. CLSI document I/ LA28-A2 (ISBN 1-56238-745-6). CLSI, 940 West Valley Road, Suite 1400, Wayne, PA 19087-1898 USA, 2011.



Ventana Medical Systems, Inc.
1910 E. Innovation Park Drive
Tucson, Arizona 85755
USA
+1 520 887 2155
+1 800 227 2155 (USA)

www.ventana.com

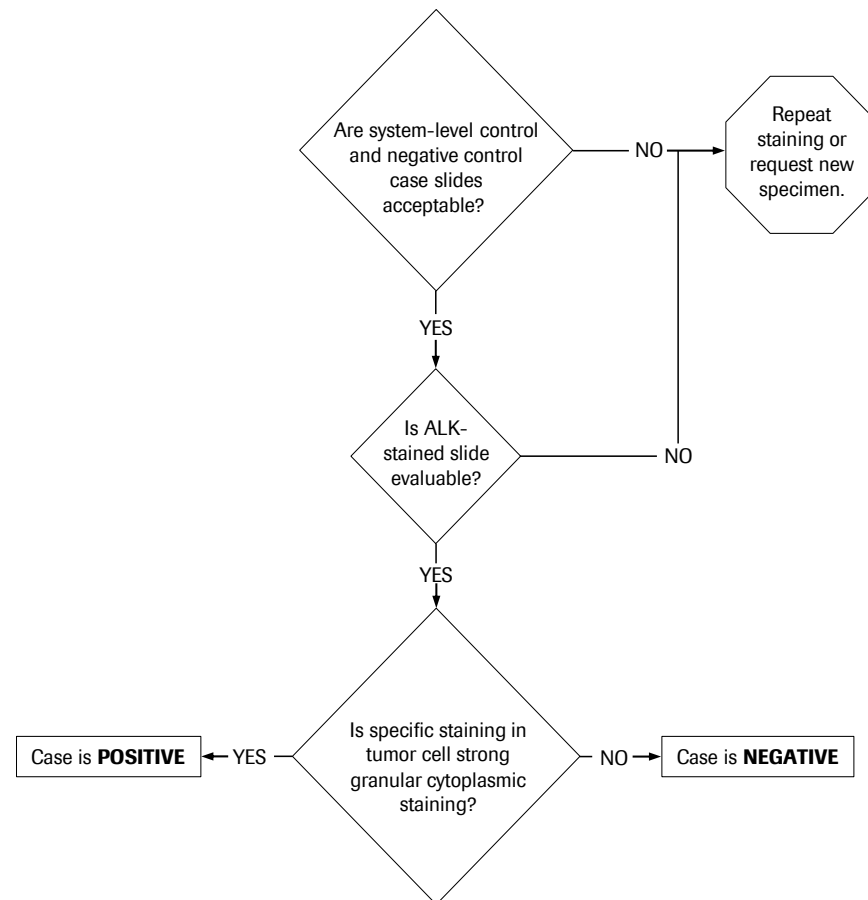
© 2015 Ventana Medical Systems, Inc.
Sold under license from



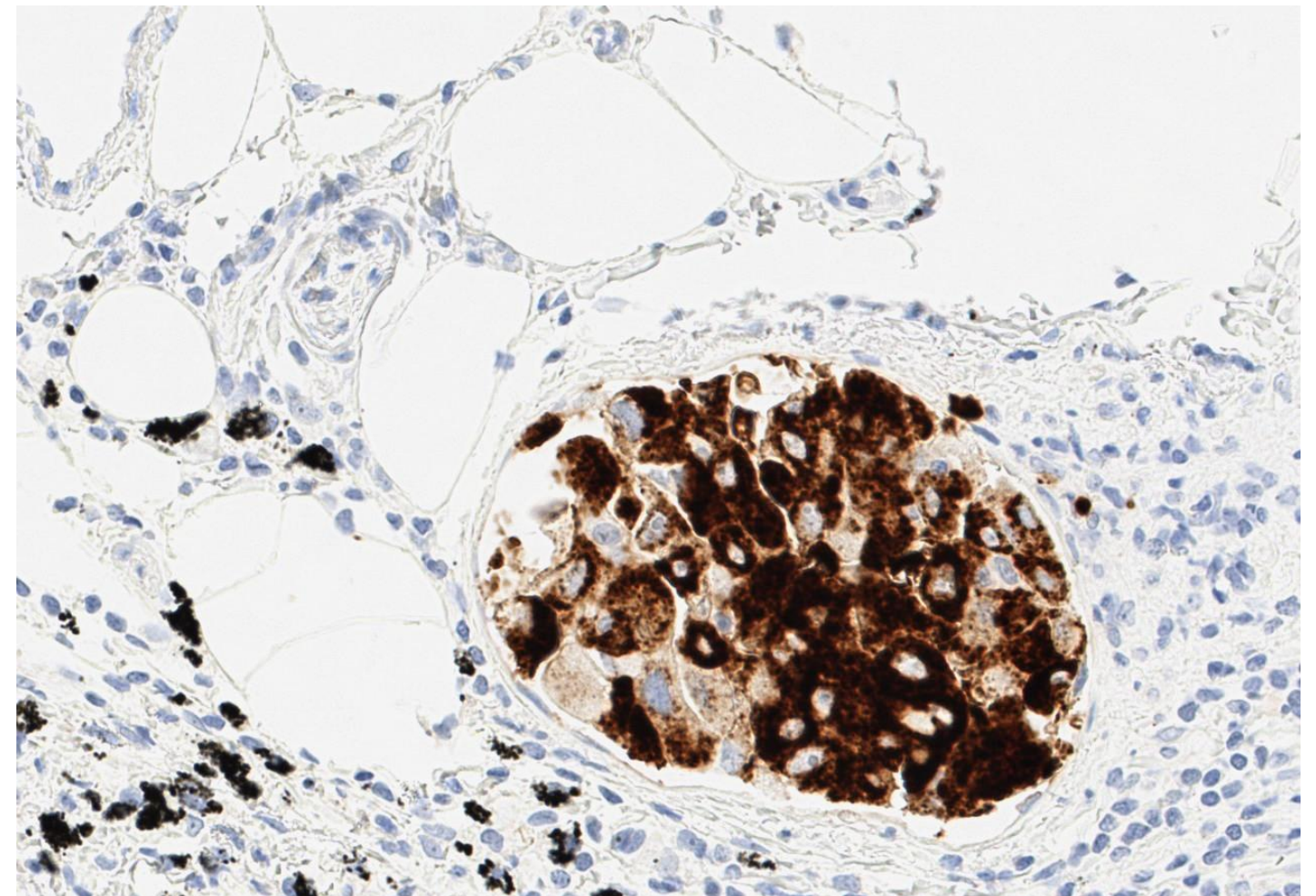
BENCHMARK, OptiView, VENTANA, and the
VENTANA logo are trademarks of Roche.
1012345USd

IVD

NSCLC ALK-Diagnosis Specimen Flow



VENTANA ALK (D5F3) CDx Assay Quick Reference Guide for Non-Small Cell Lung Carcinoma (NSCLC)



Ventana Medical Systems, Inc.
1910 E. Innovation Park Drive
Tucson, Arizona 85755
USA
+1 520 887 2155
+1 800 227 2155 (USA)

www.ventana.com

IVD

© 2015 Ventana Medical Systems, Inc.
Sold under license from

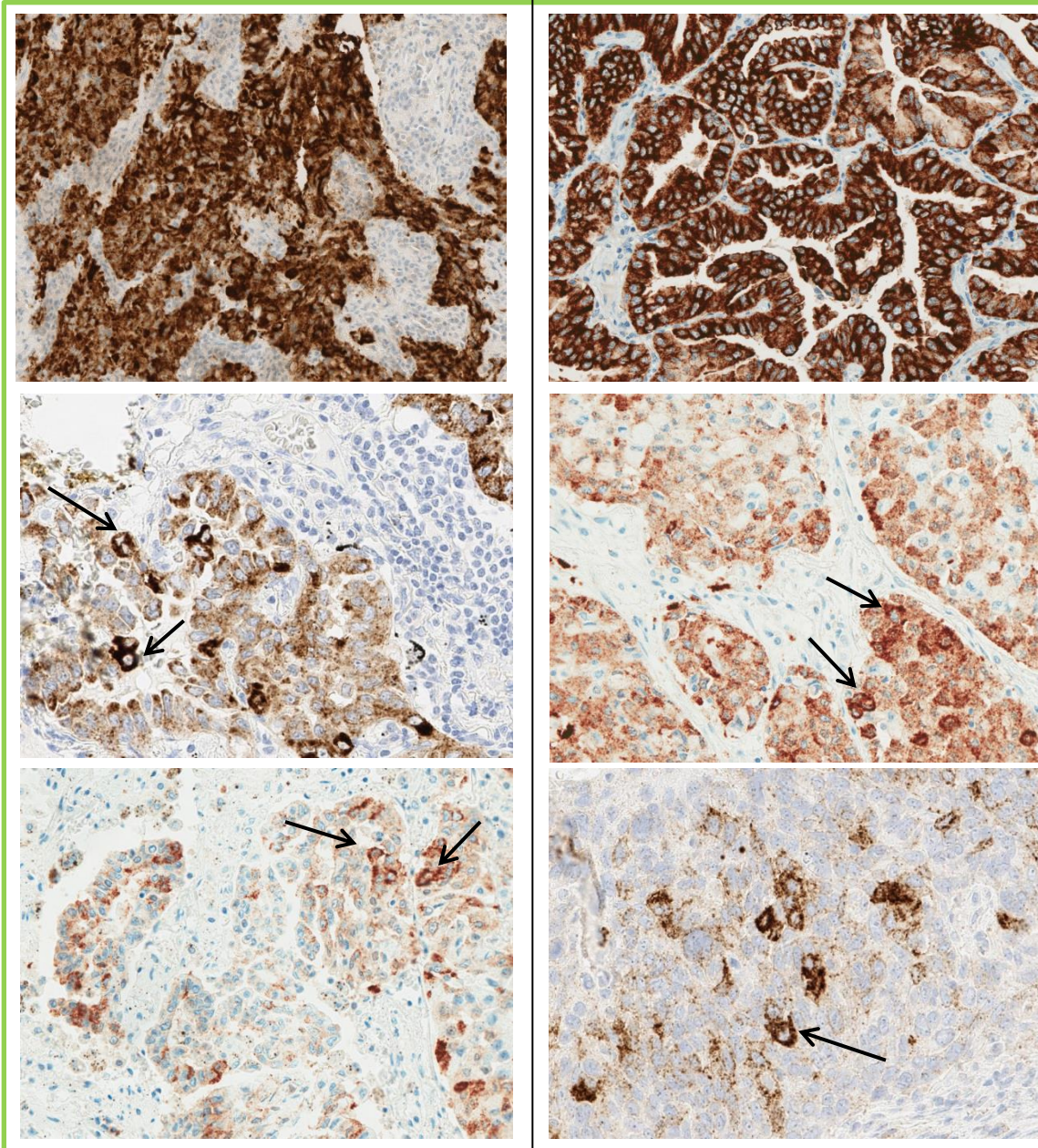


VENTANA and the VENTANA logo are trademarks of Roche.
All other trademarks are the property of their respective owners.

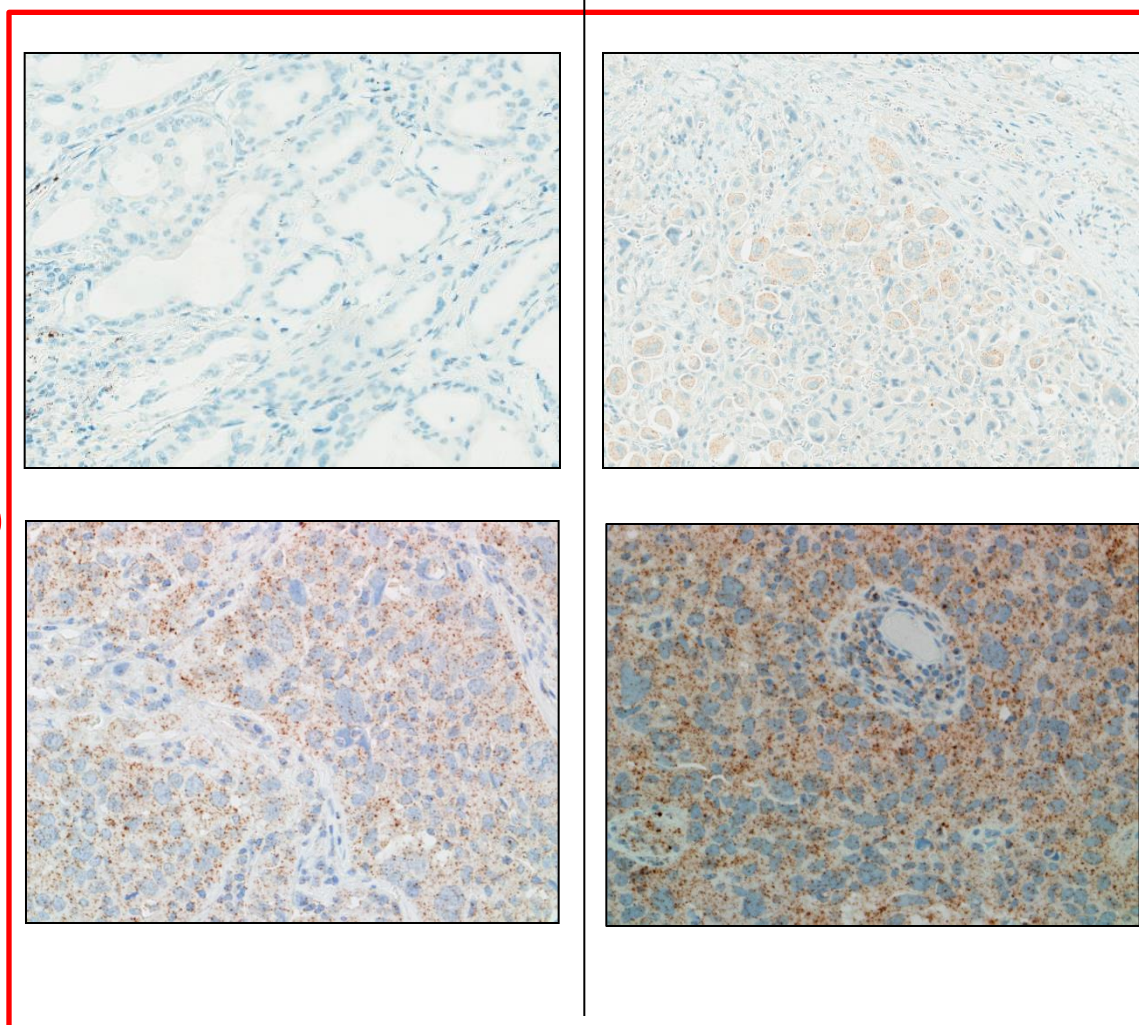
VENTANA ALK (D5F3) CDx Assay Scoring Algorithm

Clinical Interpretation	Staining Description
Positive for ALK	<p>Presence of strong granular cytoplasmic staining in tumor cells (any percentage of positive tumor cells). Certain staining artifacts should be excluded, including:</p> <ul style="list-style-type: none"> light cytoplasmic stippling in alveolar macrophages, cells of neural origin (nerve and ganglion cells), glandular epithelial staining, and scattered lymphoreticular cells within lymphocytic infiltrate. <p>Some background staining also may be observed within normal mucosa in NSCLC (including mucin) and in necrotic tumor areas, which should be excluded from the clinical evaluation.</p>
Negative for ALK	Absence of strong granular cytoplasmic staining in tumor cells.

Positive



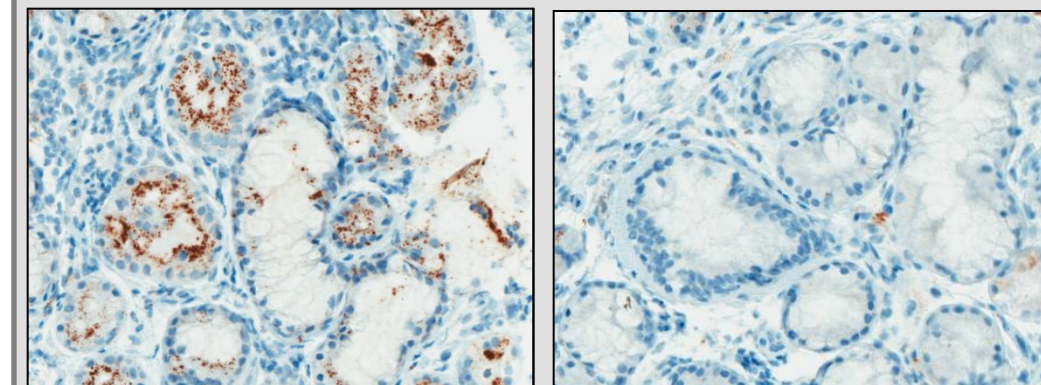
Negative



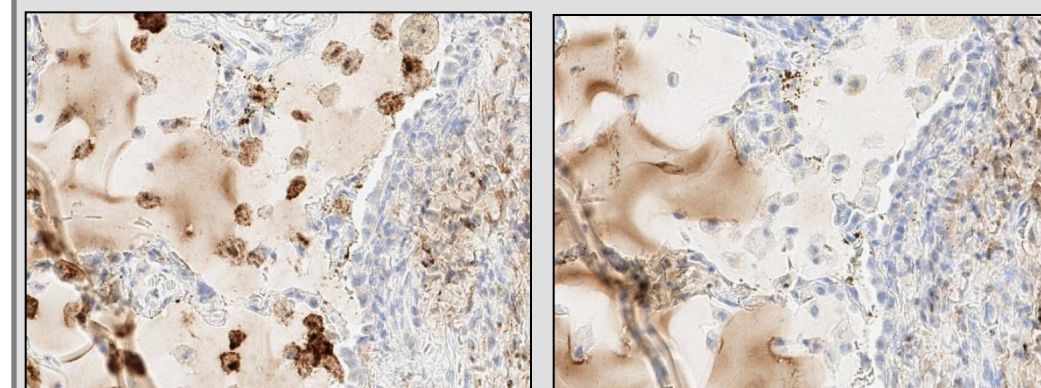
Artifacts and Background

VENTANA ALK (D5F3) CDx Assay
(left column)

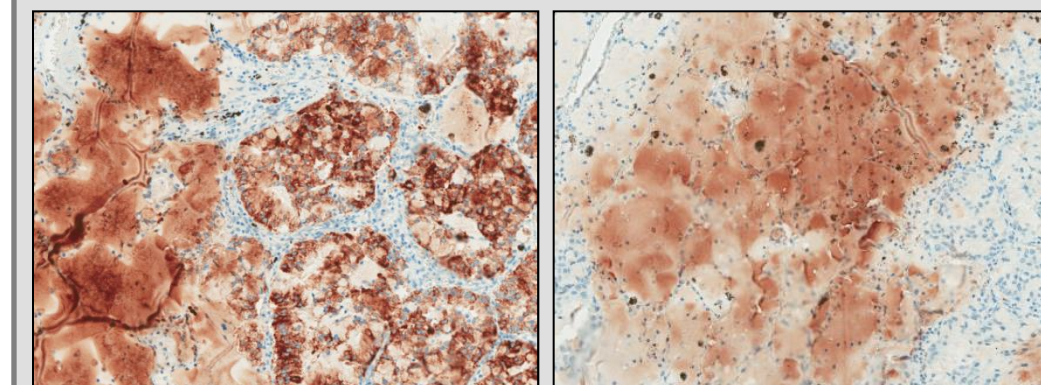
Negative Rabbit Control
(right column)



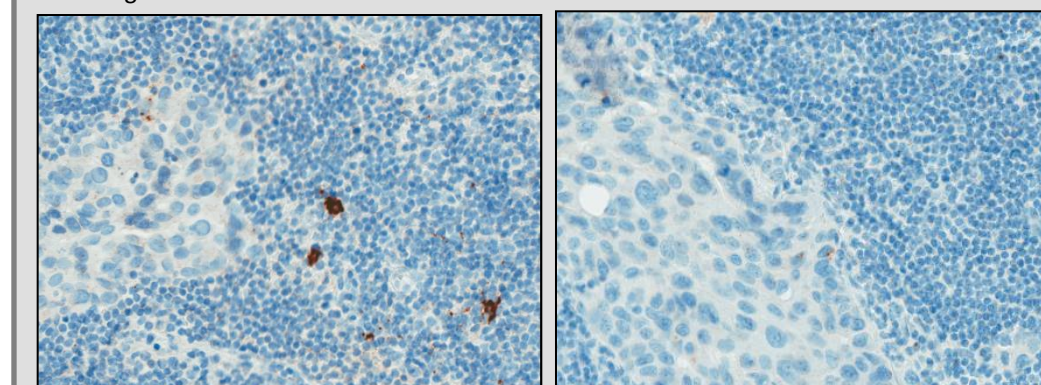
Granular cytoplasmic staining present in benign glands should be excluded for ALK interpretation.



Granular cytoplasmic staining present in alveolar macrophages should be excluded for ALK interpretation.



Mucin staining of VENTANA ALK (D5F3) CDx Assay and Rabbit Monoclonal Negative Control Ig-stained tissue. The case in the image above is positive for ALK. Mucin staining does not interfere with interpretation of the clinical diagnosis for ALK status.



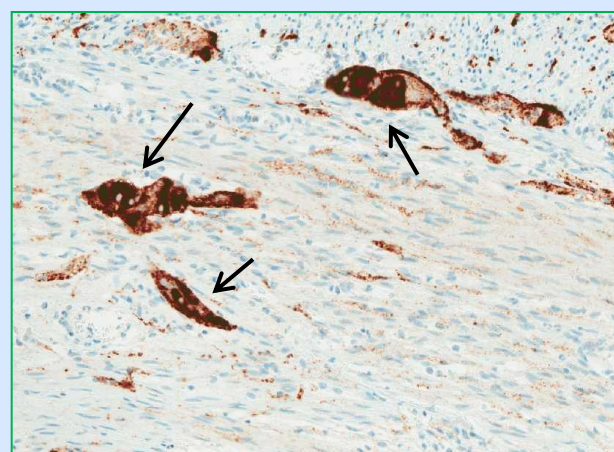
Staining present in lymphoreticular cells should be excluded for ALK interpretation.

Appendix as a Control Tissue

Acceptable	Unacceptable
Presence of strong granular cytoplasmic staining in ganglion cells. (See note)	Absence of strong granular cytoplasmic staining in ganglion cells.
Absence of strong granular cytoplasmic staining in glandular epithelial cells, muscle, and lymphoid tissue (scant or rare staining of lymphoreticular cells may be observed in lymphoid aggregates).	Excessive non-specific background staining of glandular epithelial cells, muscle, or lymphoid tissue that interferes with scoring.

Note: The nerve in appendix muscular layers show positive staining.

Acceptable ALK-positive staining of ganglion cells (arrows)



Absence of strong granular cytoplasmic staining in glandular epithelial cells, and lymphoid tissue

